

INS – 9th World Congress
Seoul, Korea
September, 2009
Scientific Abstracts
Saturday, September 12, 2009

September 12, 2009

#1

Abstract Title: The Effect of Deep Brain Stimulation on Dyskinetic Cerebral Palsy

Primary Presenter: ¹Cho SR, MD, PhD

Primary Presenter Institution:

Dept. and Research Institute of Rehabilitation Medicine, Yonsei Univ. College of Medicine, Seoul, Korea

Co-presenter(s): ¹Park HS, MD, ¹Kim ES, MD, ¹Yoon YK, MD, ²Chang JW, MD, PhD

Co-presenter(s):

¹Dept. and Research Institute of Rehabilitation Medicine, Yonsei Univ. College of Medicine, Seoul, Korea

²Dept. of Neurosurgery, Yonsei Univ. College of Medicine, Seoul, Korea

Presenting author's full street address and e-mail address:

134 Shinchon-dong, Seodaemun-gu, Yonsei Univ. Medical Center, Rehabilitation Hospital

#3104-2, Seoul, Korea, 120-752

Introduction

Dystonia is a symptom defined by involuntary, irregular contractions of the muscles during voluntary activities, causing both movement and postural disorder. These symptoms can usually be seen in cerebral palsy (CP), which is very difficult to treat. This study investigates the effect of deep brain stimulation (DBS) on dyskinetic CP showing dystonia and choreoathetosis

Materials and Methods

Eight patients, 4 with DYT1 (+) primary dystonia and 4 with dyskinetic CP, received DBS at bilateral globus pallidus internal segment (GPi). The patients with CP also received unilateral thalamotomy. All patients were checked by a dystonia rating scale (DRS) 1 month after DBS insertion, in order to evaluate the effects of DBS. Patients were also checked whether they were satisfied with the results of DBS (10 grade score; 10 being the most satisfied, 0 being unsatisfied).

Results

Generally, the use of DBS showed positive effects on dyskinetic CP as well as primary dystonia. In patients with primary dystonia, a dystonia movement scale showed an improvement from 64.50 ± 8.06 to 27.50 ± 15.33 ($p < 0.05$). A disability scale also exhibited an improvement from 12.75 ± 4.03 to 9.75 ± 4.57 ($p < 0.05$). On the other hands, in dyskinetic CP, a dystonia movement scale showed a modest improvement from 67.88 ± 13.03 to 45.25 ± 24.81 . A disability scale remained relatively the same from 16.0 ± 6.68 to 16.0 ± 7.16 . However, the subjective satisfaction score was relatively high in dyskinetic CP (4.50 ± 3.11) as well as primary dystonia (8.50 ± 1.29).

Conclusion

DBS at GPi appears to show positive effects on reducing dystonic symptoms in dyskinetic CP as well as primary dystonia. Therefore DBS might be an alternative option for dyskinetic CP with severe dystonia, who is very difficult to treat with conventional therapy.

References

Krauss JK, Loher TJ, Weigel R, Capelle HH, Weber S, Burgunder JM. Chronic stimulation of the globus pallidus internus for treatment of non-dYT1 generalized dystonia and choreoathetosis: 2-year follow. J Neurosurg 2003;98:785-92

Krauss JK. Deep brain stimulation for dystonia in adults. Overview and developments. Stereotact Funct Neurosurg 2002;78:168-82

September 12, 2009

#2

Abstract Title:

The Use of Occipital Neuromodulation to Control Appetite in Morbidly Obese Patients: A Case Series

Primary Presenter:

Roni Diaz

Primary Presenter Institution:

St. Jude Medical Neuromodulation Division, Plano, TX

Co-presenter(s):

Irene Sarosiek, Kathy Roeser, John Grant, Richard McCallum

Co-presenter(s):

Internal Medicine, Kansas University Medical Center, Kansas City, Kansas, USA

Internal Medicine, Kansas University Medical Center, Kansas City, Kansas, USA

Neurosurgery, Kansas University Medical Center, Kansas City, Kansas, USA

Internal Medicine, Kansas University Medical Center, Kansas City, Kansas, USA

Presenting author's full street address and e-mail address:

6901 Preston Road

Plano, TX 75024

roni.diaz.@sjmneuro.com

Introduction

Obesity is a major health concern in the US and is the second leading cause of preventable death. Current pharmacotherapies are useful for patients with Class I (BMI= 30-35) obesity. Patients with Class II (BMI 35-40) and III (BMI >40) are offered radical surgical interventions. Most recently neurostimulation has been hypothesized to treat obesity by modulation of appetite. Peripheral Nerve Stimulation (PNS) of the occipital (C1-C2) region to control chronic headache pain was observed to reduce appetite and resulted in substantial weight loss in some patients. The objective of this study was to examine the feasibility of using C1-C2 PNS to treat obesity by inducing early satiety in morbidly obese patients.

Materials and Methods

Five obese, but otherwise healthy subjects were subcutaneously implanted with two horizontally placed leads (Octrode[®], St. Jude Medical Neuromodulation Division, Plano, TX). Weight was evaluated after 8 weeks of continuous neurostimulation with standardized parameters delivered by an external trial stimulation device. All patients achieved at least 4% reduction in body weight and had the trial system replaced with a permanent implantable pulse generator (Eon[®], St. Jude Medical Neuromodulation Division, Plano, TX). Patient-specific parameters were then assessed on a monthly basis. Patients were not obligated to follow any dietary or lifestyle restrictions or modifications.

Results

All patients have lost weight, decreased their BMI and noticed increased satisfaction with less food intake. The most notable weight loss was 144.8 lbs over the course of 2 years. This patient began the study at 461.8 lbs and weighed 317 lbs at the last follow-up visit. Their BMI has decreased from 62.6 to 43.

Conclusion

C1-C2 occipital neurostimulation may have the potential to modify eating behavior by inducing early satiety and subsequent weight loss. Further research is indicated to evaluate this approach as a treatment option for morbidly obese patients.

Acknowledgements

This work was supported by St. Jude Medical Neuromodulation Division through a sponsored clinical research study.

Learning Objectives:

1. Discuss the feasibility of using peripheral nerve stimulation as a treatment option morbidly obese patients.
2. Review implant techniques used in peripheral nerve stimulation.
3. Understand the benefits of peripheral nerve stimulation.

September 12, 2009

#3

Abstract Title: A novel, web-based approach to public participation in neuromodulation research

Primary Presenter:

Christopher A. Harris, BSc, MSc
DPhil student, associate tutor

Primary Presenter Institution: University of Sussex, Brighton, UK

Co-presenter(s):

Laura L. Kilarski, BSc, MSc
DPhil student
University of Cardiff, Cardiff, UK

Presenting author's full street address and e-mail address:

JMS Building, University of Sussex, Falmer, Brighton, East Sussex, BN1 9QG, UK
C.A.Harris@sussex.ac.uk

Introduction

We have developed a web-resource to promote public participation in neuromodulation research. Public participation in science is challenging because non-experts often find scientific

theory demanding, and research developments are unpredictable and hence difficult to discuss in detail. To overcome these problems we focused on hypothetical, human applications of conditional rewarding brain stimulation that would be of interest to non-experts while involving important topics in neuromodulation research. Briefly, by conditional rewarding brain stimulation we mean the application of current to the reward system to reinforce desired behaviors. This technique has been used in rodents to motivate heavy physical exercise(1, 2) and problem-solving(3), and could similarly be used to motivate challenging behaviours in human patients.

Materials and Methods

We constructed a HTML/JavaScript website and a YouTube video channel. The website (~10.000 words, 16 sections) and video channel (~70 minutes, 14 videos) include information about monoamine neuroscience, functional brain stimulation and related topics. We also made use of 'web 2.0' technologies, including blogs, microblogs, social networks, web-crawlers, polls and forums. This allowed us to engage in an ongoing conversation with many interested members of the public.

Results

The website currently receives ~550 visits per month (average time on site: 3:27 minutes) and videos receive ~3000 views per month. Videos describing the functions of dopamine in the human brain rank highest in terms of popularity (~78% of views). Comments from the public however, have focused on potential risks and ethical implications of conditional rewarding brain stimulation, such as unconditional-self stimulation, deterioration of natural self-discipline, and abuse by malicious individuals or governments.

Conclusion

We created a web-resource describing a hypothetical, salient development in neuromodulation research. This approach continues to generate considerable public participation, particularly around videos detailing dopamine function and discussions about risks and implications of the technique described.

References

1. Burgess ML, Davis MJ, Borg TK & Buggy J. Intracranial self-stimulation motivates treadmill running in rats. *Journal of Applied Physiology* 1991. 71:1593-1597.
2. Garner RP, Terracio L, Borg TK & Buggy J. Intracranial self-stimulation motivates weight-lifting exercise in rats. *Journal of Applied Physiology* 1991. 71:1627-1631.
3. Hermer-Vazquez L, Hermer-Vazquez R, Rybinnik I, Greebel G, Keller R, Xu S, et al. Rapid learning and flexible memory in "habit" tasks in rats trained with brain stimulation reward. *Physiology & Behavior* 2005. 84:753-9.

Learning Objectives:

1. To understand how 'web 2.0' technologies and social media can be used to promote public participation in neuromodulation research.
2. To understand how thought-provoking, hypothetical, human applications of conditional rewarding brain stimulation can be used to promote public participation in neuromodulation research.
3. To understand how contributions from the public shape the ongoing development of this project.

September 12, 2009

#4

Abstract Title: Risks of intracranial hemorrhage in Parkinson's Disease patients receiving deep brain stimulation and ablation

Primary Presenter: Xiao-wu Hu, Professor

Department of Neurosurgery, Changhai Hospital
Shanghai, PR, China

Email: Huxiaowu25@sohu.com

Co-presenter(s):

1. Name: Xiao-ping Zhou Credentials: Professor

2. Name: Xiu-feng Jiang Credentials: Assistant Professor

Co-presenter(s):

1. Place of Employment: Department of Neurosurgery, Changhai Hospital City: Shanghai
State: Shanghai Country: PR, China

2. Place of Employment: Department of Neurosurgery, Changhai Hospital City: Shanghai
State: Shanghai Country: PR, China

Introduction

This study is to analyze risk factors of hemorrhage in a large series of deep brain stimulation(DBS) and ablation procedures in patients with advanced Parkinson's disease(PD).

Materials and Methods

Enrolled in this study were 644 patients with advanced PD treated with DBS or ablation procedures between March 1999 and December 2007 by the same surgeon, including DBS in 126 patients, ablation in 507 patients and DBS after prior unilateral ablation procedures in 11 patients. Of 796 target procedures, 207 were DBS procedures including 202 subthalamic nucleus (STN) targets, 3 ventralis intermedius nucleus (Vim) targets and 2 globus pallidus internus (GPi) targets, and the other were 589 ablation procedures including 474 GPi targets and 115 Vim targets. Postoperative CT or MRI was performed in all patients within 24 h after lead implantation or ablation treatment. Statistical correlation analysis of risk factors for intracranial hemorrhage (ICH) was performed by stepwise logistic regression. Explanatory variables were patient age, sex, blood pressure, anatomical targets, the number of microelectrode recording (MER) penetrations and surgical modality.

Results

Postoperative symptomatic ICH occurred in 10 cases (8 pallidotomy and 2 thalamotomy) and asymptomatic ICH in 14 cases (9 pallidotomy, 4 thalamotomy and 1 DBS). Hypertension and surgical modality were significantly associated with hemorrhage ($P=0.0451$, 0.0401 , respectively). The likelihood of hemorrhage in hypertensive patients was 2.455 times that in normotensive patients. The risk of causing hemorrhage in ablation was 5.362 times that in DBS. Although the number of MER trajectories not significantly correlated with ICH occurrence ($P=0.0705$), the risk of ICH would increase by 0.457 times with addition of one more trajectory MER. No statistically significant difference was found in age, sex and anatomical targets.

Conclusion

This study demonstrated that hypertension is a risk factor for ICH in PD patients. DBS is generally a safe surgical modality as compared with ablation treatment. The incremental ICH risk of one microelectrode penetration is small, but if 4-5 MER trajectories are recorded in the same target point, the risk of ICH in each target point would increase by almost two times.

September 12, 2009

#5

Abstract Title: Intracranial transplant of olfactory ensheathing cells in children and adolescent with cerebral palsy: a random controlled clinical trial

Primary Presenter:

Full Name: Hongyun HUANG Credentials: Prof. PhD. MD

Place of Employment: Beijing Hongtianji Neuroscience Academy, Department of Neurosurgery, Beijing Rehabilitation Center

City: Beijing State: Beijing Country: China

Email: hongyunh@gmail.com

Co-presenter(s):

1. Name: Lin CHEN Credentials: Associate Prof.

Co-presenter(s):

1. Place of Employment: Beijing Hongtianji Neuroscience Academy, Department of Neurosurgery, Beijing Rehabilitation Center City: Beijing State: Beijing Country: China

Abstract Title

Intracranial transplant of olfactory ensheathing cells in children and adolescent with cerebral palsy: a random controlled clinical trial

Introduction

To conduct a random controlled clinical trial (Phase I/II) to examine the benefits of using olfactory ensheathing cells (OECs) in treating cerebral palsy (CP) in children and adolescent.

Materials and Methods

Between October of 2006 and May of 2008, thirty three patients were enrolled in this clinical trial who met the following criteria: Age range: 1-12 years; Male or female, inclusive; Local physician's diagnosis of CP; Informed Consent Form signed by the patient, parents, or patient's legal guardians; The patient, parents, or patient's legal guardians are able to communicate effectively to obtain informed consent and to ensure neurological examination. They were divided into two groups randomly (treated group, n=18; controls, n=15). Aborted fetal bulb OECs were cultured and injected into the bilateral corona radiata involving the pyramidal tracts of the frontal lobes (key point for neural network restoration, KPNNR, which was first proposed by Dr Huang Hongyun in 2003). We evaluated the patients' neurological function and medical status by using Gross Motor Function Measure (GMFM-66) and Caregiver Questionnaire Scale. The data were analyzed with 2-tailed independent-sample T-test, paired-Samples T-test, and Chi-Square (χ^2) test.

Results

No patients died during this study. None of the 18 subjects in treated group experienced adverse effects or complications following the operation. Among a total of 33 patients, 14 patients (6 in the OECs treated group and 8 in the controls) completed the 6-month study; the rest were lost to follow up. Of the valid patients in the treatment group, 3 were boys and 3 girls female whose ages ranged from 2 to 12 years (mean 5.3 ± 3.8 years) at enrollment. Of the valid patients in the control group, 5 were boys and 3 were girls whose ages ranged from 2.5 to 10 years (mean 6.6 ± 2.5 years) at enrollment. The two study groups were similar at entry and the patients were comparable at baseline with respect to age ($\chi^2=0.219$, $df=1$, $p=0.640$) and sex

($t=0.767$, $p=0.458$). No significant differences were found between groups at baseline on the GMFM-66 and Caregiver Questionnaire Scale total score. The mean (\pm SD) GMFM-66 score at entry was 19.00 ± 20.00 for the treated group and 36.75 ± 27.14 for the control subjects ($t=1.346$, $p=0.203$); Caregiver Questionnaire Scale score at entry was 138.66 ± 64.06 for the treated groups and 143.75 ± 47.20 for the controls ($t=0.172$, $p=0.867$).

At the end of the 6-month follow-up period, the GMFM-66 score increased from 19.00 ± 20.00 into 26.67 ± 25.33 ($t=-2.823$, $p=0.037$) with statistically significant difference and Caregiver Questionnaire Scale score decreased from 138.66 ± 64.06 into 77.83 ± 15.99 ($t=2.100$, $p=0.090$) in treated group. For the control group, the GMFM-66 score decreased from 36.75 ± 27.14 into 33.75 ± 25.44 ($t=1.101$, $p=0.307$) with no remarkable difference and Caregiver Questionnaire Scale score decreased from 143.75 ± 47.20 into 119.25 ± 40.33 ($t=2.229$, $p=0.061$).

The mean (\pm SD) rate of change for the GMFM-66 total score was 7.67 ± 6.65 for the treated group and -3.00 ± 7.71 for the controls ($t=-2.710$, $p=0.019$) with statistically significant difference, whilst the Caregiver Questionnaire Scale score was 60.83 ± 70.97 for the treated group and 24.50 ± 31.08 for the controls ($t=-1.173$, $p=0.282$) during the 6 months.

Conclusion

Our study indicates OEC KPNNR transplantation, in addition to being well-tolerated, is able to play a promising role on improving a certain degree of function of CP in children and adolescent through the neural repair.

Acknowledgements

Beijing Hongtianji Neuroscience Academy Funding

Please acknowledge any funding sources and contributors to the research in this section.

References

1. Huang H, Chen L, Xi H, Wang Q, Zhang J, Liu Y, et al. Olfactory ensheathing cells transplantation for central nervous system diseases in 1,255 patients. *Zhongguo Xiu Fu Chong Jian Wai Ke Za Zhi*. 2009;23(1):14-20
2. Shyu WC, Liu DD, Lin SZ, Li WW, Su CY, Chang YC, et al. Implantation of olfactory ensheathing cells promotes neuroplasticity in murine models of stroke. *J Clin Invest*. 2008;118(7):2482-95
3. Park KI, Himes BT, Stieg PE, Tessler A, Fischer I, Snyder EY. Neural stem cells may be uniquely suited for combined gene therapy and cell replacement: Evidence from engraftment of Neurotrophin-3-expressing stem cells in hypoxic-ischemic brain injury. *Exp Neurol*. 2006;199(1):179-90.
4. O'Shea M. Cerebral palsy. *Semin Perinatol*. 2008;32(1):35-41.
5. Hoare B, Imms C, Carey L, Wasiak J. Constraint-induced movement therapy in the treatment of the upper limb in children with hemiplegic cerebral palsy: a Cochrane systematic review. *Clin Rehabil*. 2007;21(8):675-85.

e.g. Author 1 , Author 2, Author 3, Author 4, Author 5, Author 6, et al. Title. Journal Year. Volume: start page-end page.

Learning Objectives:

1. This is a first report of a random controlled clinical trial of Intracranial transplant of olfactory ensheathing cells in children and adolescent with cerebral palsy
2. This is a useful treatment of neurorestoratology.
3. Combined comprehensive neuronrestorative procedure is advanced idea for the treatment of CP.

September 12, 2009

#6

Does CSF leakage influence the electrode localization after deep brain stimulation surgery?

Yong Hwy Kim, MD¹, Yong Hoon Lim, BS¹, Hee Jin Kim, MD², Jee-Young Lee, MD⁶,
Cheolyoung Kim, PhD⁷, Dong Gyu Kim, MD^{1,5}, Beom Seok Jeon, MD^{2,5},
and Sun Ha Paek, MD^{1,3,4,5}

¹Department of Neurosurgery and ²Department of Neurology,
³Hypoxic/Ischemia Disease Institute, ⁴Cancer Research Institute, Seoul National University
College of Medicine, Seoul, Korea,
⁵Clinical Research Institute Seoul National University Hospital
⁶Department of Neurology, Inje University College of Medicine, Goyang, Korea
⁷Medical Imaging Laboratory, CyberMed, Inc., Seoul, Korea

Financial Disclosure: Authors disclosed no conflict of interest.

Objective We compared the electrode positions estimated at the immediate postoperative period in comparison with those estimated at six months after bilateral subthalamic nucleus (STN) deep brain stimulation (DBS).

Materials and Method Brain CT scans were taken immediately and at 6 months after bilateral STN DBS in 53 Parkinson's disease (PD) patients. The two images were fused using the mutual information technique. The discrepancies of electrodes in three coordinates were measured in the fused images and the relationship with the pneumocephalus was evaluated.

Results The average discrepancy of x- and y-coordinates of electrode positions at the level of STN (3.5mm below the AC-PC line) in the fused images were 0.6 ± 0.5 mm (range:0 ~ 2.1 mm) and 1.0 ± 0.8 mm (range:0 ~ 5.2mm), respectively. The average discrepancy of z-coordinates of the electrode tips of the fused images was 1.0 ± 0.8 mm (range:0.1 ~ 4.0 mm). The volume of pneumocephalus (range: 0~76 ml) was correlated with the y-coordinate discrepancies ($p < 0.005$).

Conclusion The electrode positions in the immediate postoperative CT might have significant discrepancies with those in the CT taken at a stable period after bilateral STN DBS when there is a large amount of pneumocephalus.

Key Words: CT, CSF leakage, Electrode localization, Parkinson's disease, STN DBS

September 12, 2009

#7

Abstract Title: Is MRI a reliable tool to locate the electrode after deep brain stimulation (DBS) surgery? Comparison study of CT and MRI for the localization of electrodes after DBS

Primary Presenter: Ji Yeoun Lee, M.D.

Primary Presenter Institution:

Clinical fellow, Dept of neurosurgery, Seoul National University Hospital, Seoul, Korea

Co-presenter(s): Sun-Ha Paek, M.D., Ph.D.

Co-presenter(s): Assistant professor, Dept of neurosurgery, Seoul National University Hospital, Seoul, Korea

Presenting author's full street address and e-mail address:

Seoul National University Hospital 5th floor, 28 Yeongeon-dong Chongro-gu Seoul, Korea
femiddang@hanmail.net

Introduction

Postoperative assessment of the electrode position is important in the estimation of clinical outcome after deep brain stimulation. MRI has been utilized to estimate the electrode position but questioned about the accuracy due to image distortion. The purpose of this study was to validate the accuracy of electrode localization by MRI in comparison with CT scan.

Materials and Methods

61 patients who had undergone bilateral STN DBS between March 2005 and October 2006 and taken both MRI and CT at least 6 months after bilateral STN DBS were enrolled for the analysis. The fused images of the postoperative brain MRI and the brain CT by using the mutual information technique were realigned along the midsagittal anterior commissure (AC)-posterior commissure (PC) line. The x- and y-coordinates of the centers of electrodes shown in CT and MRI were compared to calculate average discrepancy of electrode position estimated in CT and MRI at five different levels; 30mm, 20mm, 10mm above, 3.5 mm below, and at the AC-PC level. The discrepancy of the z-coordinates of the tips of the electrodes shown in the brain MRI and CT was also calculated.

Results

The average discrepancy of x-coordinates between MRI and CT were 0.16mm \pm 0.89mm at 30mm above the AC-PC plane, 0.05mm \pm 0.78mm at 20mm above, 0.04mm \pm 0.70mm at 10mm above, 0.04mm \pm 0.76mm at the level of AC-PC plane, and 0.08mm \pm 0.71mm at the level of STN which was measured 3.5mm below the plane.

The average discrepancy of y-coordinates between MRI and CT were -1.11mm \pm 0.66mm at 30mm above the AC-PC plane, -1.12mm \pm 0.64mm at 20mm above, -1.0mm \pm 0.70mm at 10mm above, -1.0mm \pm 0.66mm at the level of AC-PC plane, and -0.70mm \pm 0.62mm at the level of STN which was measured 3.5mm below the plane. The average discrepancy of z-coordinates of the tips of electrodes estimated in MRI and CT were -0.99mm \pm 0.52mm.

Average distances between the electrode shown on MRI and CT were 1.38mm at 30mm above the AC-PC plane, 1.33mm at 20mm above, 1.31mm at 10mm above, 1.30mm at the level of AC-PC plane, and 1.06mm at the level of STN which was measured 3.5mm below the plane.

Conclusion

The results suggested that there was a significant discrepancy of the centers of electrodes estimated in CT and MRI, especially in the y- and z-coordinates and MRI might not be a reliable tool to assess the electrode position after DBS surgery.

Figure and Table Legend

Figure 1. Image fusion of brain CT and MRI taken at six months after STN DBS by using mutual information technique.

The electrode is seen as an irregular round shape (arrow) in the T2WI axial view at the STN level (3.5mm below the AC-PC plane) (A). The electrode extracted from the CT is marked in red sphere in the axial view after fusion with MRI by using mutual information technique (B). The big blue arrow shows the center of the artifact on the MRI and small slanted arrow, depicted as 1.1mm is the distance between the center of the electrode on CT and MRI (C). The differences of electrode position in x- and y-coordinates are measured with direction (D). The difference of electrode position in z-coordinates is also measured (E).

Figure 2. Visualization of electrodes in the fused image of brain CT and MRI. T2WI sagittal view showing the AC-PC line (horizontal blue line) and the 5 levels are marked in vertical blue lines (A). At the lowest level, 3.5 mm below the AC-PC line, the subthalamic nucleus is well visualized along with the red nucleus and putamen (B). At the level of the AC-PC line, putamen is usually seen in this level (C). At the level 10 mm above the AC-PC line, the septum pellucidum, thalamus, and the caudate nucleus, third ventricle, fornix are well visualized (D). At 20 mm above the AC-PC line where the corpus callosum, caudate nucleus, and lateral ventricles are usually visible (E). At 30 mm above the AC-PC line, the lateral ventricle and centrum semiovale are visible (F).

Figure 3. 3-D visualization of electrodes in the fused image of brain CT and MRI.

Table 1. Measured values of distance,x,y,z at each level

Learning Objectives:

1. How is the position of the electrode evaluated after deep brain stimulation?
2. What are the advantage and disadvantage of imaging modalities performed after electrode insertions?

September 12, 2009

#8

Abstract Title: Revision of deep brain stimulation electrodes: A single center experience

Primary Presenter: Jae-Sung Park, MD

The Cleveland Clinic Foundation

Cleveland, Ohio, USA

Email: nsjasonpark@hotmail.com or parkj2@ccf.org

Co-presenter(s):

1. Name: Milind Deogaonkar Credentials: MD
2. Name: Andre Machado Credentials: MD
3. Name: Ali Rezai Credentials: MD

Co-presenter(s):

The Cleveland Clinic City: Cleveland, OH, USA

Introduction

To analyze the incidence, causes, technical nuances and complication associated with revision of deep brain stimulation (DBS) carried out at our center

Materials and Methods

A retrospective review after IRB approval was conducted for 44 revision surgeries among over 1000 DBS surgeries between 2004 and 2008. A chart review was carried out to look for targets of initial implantation, causes for revision, technical details and complications.

Results

Out of 44 revisions, twenty-nine leads were initially implanted in the subthalamic nucleus (STN); eight in the Thalamus and seven in the Globus pallidus interna (Gpi). Electrode breakage was the most common (20 out of 44) condition that led to the re-implantation, followed by misplacement of the lead (13), infection (9) and migration (2). The mean duration between the initial surgery and the removal of the lead was longer in electrode breakage (146.7 weeks) and misplacement (192.4 wks) than those in infection (73.2 wks) and migration (58.2 wks), while the mean duration between the removal of the lead and the re-implantation was the longest in infection cases (29.6 wks versus 0~5 wks). Every re-implantation was performed using Leksell frame with microelectrode recording (MER) and macrostimulation, except for 11 cases replacing broken electrode that did not require MER and one infection case that was undertaken using frameless technique. Thirty-nine (88.6%) of 44 re-implantations resulted in improvement of outcome, whereas the remaining 5 did not: 4 implantations for 3 dystonia patients and one for an essential tremor patient. Mean corrected distances in misplacement and migration cases were 6.5 (± 1.27 , 1.9~18.1) mm and 16.4 (± 6.22 , 10.2~22.6) mm, respectively.

Conclusion

DBS lead revision was needed in approximately 4% of the patient with lead break being the commonest cause. All re-implantations were done stereotactically resulting in a good post-operative outcome.

Learning Objectives:

1. To understand variable causes and approaches for re-operations following a DBS procedure.

September 12, 2009

#9

Abstract Title: Effects of Pallidal Deep Brain Stimulation in Primary Cervical Dystonia with Phasic Type

Primary Presenter: Myung-Ki, Lee M.D.

Primary Presenter Institution: Department of Neurosurgery, Bongseng Memorial Hospital, Busan, Korea

Co-presenter(s): Seung-Kyu, Jeung, M.D. Chang-Ghu, Ghang M.D.

Co-presenter(s):

Department of Neurosurgery, Bongseng Memorial Hospital, Busan, Korea

Presenting author's full street address and e-mail address:

68-11, Zwachun-dong, Dong-gu, Busan, Republic of Korea.

stereomk@naver.com

Introduction

The phasic type of cervical dystonia (CD) is characterized by the feature of abnormal mobile attitude of the head. we assessed experiences in 6 patients of severe medically refractory primary CD with only continuous phasic type treated by bilateral globus pallidus internus (Gpi)-deep brain stimulation(DBS).

Materials and Methods

Between May 2006 and December 2008, Six patients underwent bilateral implantation of DBS leads (DBS Model 3389, Medtronic) into the within Gpi. The final implantation site was refined by a combination of direct visualization on MRI, microelectrode recordings, and intraoperative stimulation. The surgical procedure was performed under local anesthesia. After 1 to 3 days (mean, 2.4) of a trial test at ward, the stimulation device was implanted subcutaneously under the general anesthesia. Implantable pulse generator was programmed on the first postoperative day. Patients were evaluated with the Toronto Western Spasmodic Torticollis Rating Scale (TWSTRS) before surgery and postoperatively. Relief scale was assessed using patient self-reporting of subjective improvement in percentage.

Results

The duration of the CD was 5.7 ± 3.6 years (range 1-10). The age of patients at surgery was 54.2 ± 10.2 years (range 35-64). The follow-up period was 18.7 ± 11.1 months (range 3-35). Five of six patients were available for analysis of more than one year. The TWSTRS total scores improved 64.5%, 65.5%, 75.8%, and 76.0% by at 3-months, 6-months, 12 months, postoperatively and the last available follow-up, respectively. All aspects of the TWSTRS subscores including severity, disability and pain improved at about similar rate. Subjective improvement reported by the patient averaged $81.7 \pm 6.8\%$. Stimulation parameters at the last follow-up were: frequency, 130 ± 0 Hz; pulse width, 200 ± 15 (the right) or 185 ± 45 (the left) microseconds; and amplitude, 3.4 ± 0.7 V. Neither major complications nor neurological deterioration was observed.

Conclusion

Bilateral Gpi-DBS in patients for primary CD with continuous phasic type, led to significant and gradual improvement up to 6-months of follow-up duration and thereafter, the improvement sustained. Our results support that the bilateral Gpi-DBS is a very effective tool in severe medically refractory primary CD with phasic type.

References

Zelma H. T. Kiss¹, Kristina Doig-Beyaert¹, Michael Eliasziw^{1,2}, Joseph Tsui⁴, Angela Haffenden^{1,3}, Oksana Suchowersky¹. The Canadian multicentre study of deep brain stimulation for cervical dystonia.
Brain 2007 130(11):2879-2886

Learning Objectives:

1. Deep brain stimulation (DBS) of the globus pallidus intrnus (Gpi) has been proposed as a treatment for intractable phasic CD, but small case series often combined different types of CD such as tonic or tremulous type, and assessing the outcome of each types to the pallidal DBS was limited.
2. To know the outcome of severe medically refractory primary CD with only continuous phasic type treated by bilateral Gpi-DBS.

September 12, 2009

#10

Abstract Title: Securing of Deep Brain Stimulation Connector by Placing a Trough in the Cranial Bone: Technical note

Primary Presenter: Myung-Ki, Lee M.D.

Primary Presenter Institution: Department of Neurosurgery, Bongseng Memorial Hospital, Busan, Korea

Co-presenter(s): Seung-Kyu, Jeung, M.D. Chang-Ghu, Ghang M.D.

Co-presenter(s):

Department of Neurosurgery, Bongseng Memorial Hospital, Busan, Korea

Presenting author's full street address and e-mail address:

68-11, Zwachun-dong, Dong-gu, Busan, Republic of Korea

stereomk@naver.com

Introduction

The authors report a surgical method to secure the lead-extension connector of deep brain stimulation (DBS).

Materials and Methods

A vertical skin incision was made about 6 cm in length at the posterior parietal area. We drilled a trough in the posterior parietal bone to decrease the profile of the connector and also to indwell an excess lead-extension line. Multiple side holes were made along the trough edge to anchor them. After then, galea closure was done. This technique has been used to secure 46 DBS connectors implanted for movement disorder including parkinson's disease (14 patients), dystonia (6 patients), and essential tremor (1 patient). The follow-up period was 9.6 ± 8.2 months (range 2-13).

Results

The complication was not related to this technical process. But, dura exposure was noted in 6.8 % of 46 procedures, but dural tearing did not occur. The connector was seldom noticeable in appearance. Neither scalp infection and/or erosion at the connector site nor migration of the connector developed. Tolerable discomfort at site of the skin incision occurred transiently in the most cases.

Conclusion

The securing of DBS connector using a trough in the cranial bone appears to be a safe method to prevent scalp infection and/or erosion, and yet long-term follow-up is needed.

References

Clement Hamani, Andres M. Lozano Hardware-Related Complications of Deep Brain Stimulation: A Review of the Published Literature
Stereotact Funct Neurosurg 2006;84:248-251

September 12, 2009

#11

Abstract Title: Transcranial Direct Current Stimulation (TDCS): What happens on the healthy cortex?

Primary Presenter: Mark Plazier, M.D.

Primary Presenter Institution:

Department of Brain and Neurosurgery, University Hospital Antwerp, Wilrijkstraat 10, 2650 Edegem, Belgium

Co-presenter(s):

Kathleen Joos^a, Sven Vanneste^a, Jan Ost^a, Elsa van der Loo^a, Tomas Menovsky^a, Marco Congedo^b, Dirk De Ridder^a

Co-presenter(s):

^aDepartment of Brain and Neurosurgery, University Hospital Antwerp, Wilrijkstraat 10, 2650 Edegem, Belgium

^bNational Center for Scientific Research (CNRS), GIPSA-lab, Grenoble, France

Presenting author's full street address and e-mail address:

Department of Brain and Neurosurgery, University Hospital Antwerp, Wilrijkstraat 10, 2650 Edegem, Belgium

e-mail: mark.plazier@uza.be

Introduction

The use of Transcranial Direct Current Stimulation (TDCS) in research setting is gaining terrain. By applying a low direct current of 1.0 up to 2.0 mA to the scalp, neural excitability is influenced [1]. Among the clinical trials effects are shown in pathologies like chronic pain, fibromyalgia, Parkinson, stroke as well as tinnitus and depressive disorders [2], although underlying working mechanisms are still unknown.

The effects of TDCS on cortical activity in healthy subjects are presented using LORETA (Low Resolution Electrical Tomography) current source densities [3, 4].

Materials and Methods

15 healthy student males (21-24 years), were included in this randomized placebo controlled study. Baseline mood scales (Profile of Mood State 32, Fatigue Impact Questionnaire, Positive and Negative Affects Scores) were acquired, as well as a baseline 19 channel EEG (500 Hz sampling rate, eyes closed) prior to randomisation. 3 different settings were tested: a) placebo TDCS b) bifrontal tdcS, kathode placement right dorsolateral prefrontal cortex c) bifrontal tdcS, kathode placement left dorsolateral prefrontal cortex.

After each setting mood scales were acquired as well as an EEG.

After artefact rejection, LORETA current source densities were compared with T-within subject tests.

Results

Significant changes were found for fatigue, affect and mood changes on the questionnaires. According to these changes EEG results showed significant changes in cortical activity in the orbitofrontal gyrus, cingulate gyrus, amygdala, parahippocampal region, insula and dorsolateral prefrontal cortex.

Conclusion

These results demonstrate a wide-spread effect of tDCS, in cortical structures described in pain, anxiety and depression literature [5, 6].

TDCS might become an interesting tool in neuromodulation as a non-invasive treatment or could be evaluated as a prognostic test for invasive treatment. As the working mechanisms of this weak direct current are still unknown further research is necessary to elucidate the full application spectrum of this device.

References

1. Wagner, T., et al., *Transcranial direct current stimulation: a computer-based human model study*. Neuroimage, 2007. 35(3): p. 1113-24.
2. Michael A. Nitsche, L.G.C., Eric M. Wasserman, Alberto Priori, Nicolas Lang, Andrea Antal, Walter Paulus, Friedhelm Hummel, Paulo S. Boggio, Felipe Fregni, Alvaro Pascual-Leone, *Transcranial direct current stimulation: State of the art 2008*. Brain Stimulation, 2008. 1(1): p. 206-223.
3. Pascual-Marqui, R.D., C.M. Michel, and D. Lehmann, *Low resolution electromagnetic tomography: a new method for localizing electrical activity in the brain*. Int J Psychophysiol, 1994. 18(1): p. 49-65.
4. Pascual-Marqui, R.D., et al., *Functional imaging with low-resolution brain electromagnetic tomography (LORETA): a review*. Methods Find Exp Clin Pharmacol, 2002. 24 Suppl C: p. 91-5.
5. Apkarian, A.V., et al., *Human brain mechanisms of pain perception and regulation in health and disease*. Eur J Pain, 2005. 9(4): p. 463-84.
6. Mayberg, H.S., *Defining the neural circuitry of depression: toward a new nosology with therapeutic implications*. Biol Psychiatry, 2007. 61(6): p. 729-30.

Figure and Table Legend

Figure 1: Changes in Current Source Density in Theta band after TDCS

September 12, 2009

#12

Abstract Title: Prolonged cortical stimulation in large sensorimotor cortical infarct model

Primary Presenter: Yong-Il Shin, M.D., Ph.D.

Department of Rehabilitation Medicine, Wonkwang University School of Medicine
Iksan, Korea

Email: cbrmshin@wku.ac.kr

Co-presenter(s):

1. Name: Seong-Keun Moon Credentials: M.D., Ph.D.
2. Name: Hyojoon Kim Credentials: M.D.
3. Name: Hyoung-Ihl Kim Credentials: M.D., Ph.D.

Co-presenter(s):

1. Department of Neurosurgery, Wonkwang University School of Medicine, Korea
2. Department of Neurosurgery, Presbyterian Medical Center, Jeonju, Korea
3. Department of Neurosurgery, Presbyterian Medical Center, Jeonju, Korea

Introduction

Animal studies of cortical infarction in sensorimotor cortex indicate direct cortical stimulation in peri-infarct area combined with concurrent rehabilitative training significantly enhances motor recovery. We studied the effect of prolonged cortical stimulation on motor recovery and relationship between the size of infarct and stimulation pattern to find better strategy in cortical infarct model.

Materials and Methods

Eighty-two Sprague Dawley rats were used for behavioral training in the single pellet reaching task (SPRT) was performed for two weeks before surgery. Unilateral photothrombotic infarction was induced in the sensorimotor cortex opposite the preferred paw using Rose Bengal dye and cold light. A stimulating electrode was implanted immediately after induction of cortical lesions in all rats. Animals were randomly divided into Large lesion group (LLG : 6mm lesion) and Small lesion group (SLG: 4 mm lesion). Animals were further subdivided into three groups based on the duration of cortical stimulation: (1) sham-stimulated, (2) Continuous stimulation (CSG), and (3) Intermittent stimulation (ISG), Electrical stimulation (half threshold, 50Hz & 194 pulse duration) was delivered from the second day after operation throughout 2 weeks. Postoperatively, all rats were trained in the same manner as preoperative behavioral training.

Results

SLG animals with intermittent stimulation (ISG) showed significantly better improvement of reaching success compared to sham-stimulated on 5th, 6th, 8th, 12th, and 13th post-lesion training days. In contrast, CSG did not significantly influence reaching success. In LLG animal's continuous stimulation (CSG) produced significant improvement on the 5th through 13th post-lesion days compared with sham-stimulated animals. However, ISG did not produce significantly better recovery than sham-stimulation.

Conclusion

Prolonged cortical stimulation may be a promising option to enhance motor recovery in photothrombotic infarct model rats. However, pattern and duration of stimulation requires modification depending on the extent of infarct.

Acknowledgements

* This research was supported by Korean Research Foundation (KRF-2006-311-E00426).

Learning Objectives:

1. To evaluation of the effect of prolonged cortical stimulation on stroke motor recovery
2. To evaluation of the relationship between the size of infarct and stimulation pattern to find better strategy in cortical infarct model.
3. To understand of cortical plasticity on stroke

September 12, 2009

#13

Abstract Title: Pallidal DBS in a Child with Lesch Nyhan Syndrome Produces Rapid Symptomatic Improvement

Primary Presenter: Konstantin V. Slavin, MD

Primary Presenter Institution: University of Illinois at Chicago, Chicago, IL, USA

Co-presenter(s): Miriam A. Kalichman¹, MD, Deborah J. Gaebler-Spira², MD, Cynthia L. Booth¹, RN, Eduardo Goellner¹, MD

Co-presenter(s): ¹University of Illinois at Chicago, Chicago, IL, and ²Rehabilitation Institute of Chicago, Chicago, IL, USA

Presenting author's full street address and e-mail address:

Department of Neurosurgery, M/C 799, 912 South Wood Street, Chicago, Illinois 60612, USA
kslavin@uic.edu

Introduction

Lesch Nyhan syndrome (LNS) is an inborn metabolic disease that presents with severe generalized dystonia and self-mutilation behavior. Here we present our preliminary experience with a patient with LNS who exhibited impressive symptomatic improvement with use of bilateral pallidal deep brain stimulation (DBS).

Materials and Methods

An 8-year old boy was diagnosed with LNS at the age of 18 months. His generalized dystonia was noted at infancy; the self-mutilating behavior started at age 4 with finger biting and lower lip traumatic amputation. He underwent extraction of upper incisors, could not attend school due to frequent prolonged absences and required constant use of elbow restraints. At age 6, patient developed an episode of severe dystonia with hyperthermia and rhabdomyolysis. An intrathecal baclofen (ITB) provided symptomatic improvement, but the pump had to be removed due to infection few weeks after implantation.

Based on initial encouraging experience from Japan, Switzerland and France⁽¹⁻³⁾, bilateral DBS device was implanted into globus pallidus under general anesthesia in one sitting at the age of 7 years and 10 months.

Results

Within 3 months after the DBS treatment initiation, an improvement in dystonia was noted along with marked decrease in self-mutilation behavior to the point that restraints were no longer required. Although improvement in dystonia is similar to the one observed during ITB administration, behavioral changes appear to be unique to DBS treatment. A positive dynamics in symptomatic improvement continues during ongoing follow up.

Conclusion

Pallidal DBS appears to be effective in treatment of motor and behavioral symptoms of LNS. Our anecdotal experience supports findings from other 4 cases of LNS treated with pallidal DBS that were reported previously.

References

1. Taira T, Kobayashi T, Hori T. Disappearance of self-mutilating behavior in a patient with lesch-nyhan syndrome after bilateral chronic stimulation of the globus pallidus internus. Case report. *J Neurosurg.* 2003; 98: 414-6.
2. Pralong E, Pollo C, Coubes P, Bloch J, Roulet E, Tétreault MH, Debatisse D, Villemure JG. Electrophysiological characteristics of limbic and motor globus pallidus internus (GPI) neurons in two cases of Lesch-Nyhan syndrome. *Neurophysiol Clin.* 2005; 35: 168-73.
3. Cif L, Biolsi B, Gavarini S, Saux A, Robles SG, Tancu C, Vasques X, Coubes P. Antero-ventral internal pallidum stimulation improves behavioral disorders in Lesch-Nyhan disease. *Mov Disord.* 2007; 22: 2126-9.

Learning Objectives:

Upon completion of this educational activity, attendee will be able to:

1. Describe clinical features of Lesch Nyhan syndrome
2. Discuss benefits of pallidal neurostimulation in Lesch Nyhan syndrome patients
3. Understand limitations related to anecdotal experience in using neurostimulation related to this rare neurological condition

September 12, 2009

#14

Abstract Title: Prevention and treatment of cerebral vasospasm following subarachnoid hemorrhage with cervical spinal cord stimulation

Primary Presenter: Konstantin V. Slavin, MD

Primary Presenter Institution: University of Illinois at Chicago, Chicago, IL, USA

Co-presenter(s): Eduardo Goellner, MD; Nada Mlinarevich, MPH; Karriem Watson, MD

Co-presenter(s): University of Illinois at Chicago, Chicago, IL, USA

Presenting author's full street address and e-mail address:

Department of Neurosurgery, M/C 799, 912 South Wood Street, Chicago, Illinois 60612, USA

kslavin@uic.edu

Introduction

Cerebral vasospasm following aneurysmal subarachnoid hemorrhage (aSAH) remains the major source of morbidity and mortality despite variety of prophylactic and therapeutic interventions. Goal of this study was to establish feasibility and safety of prolonged cervical spinal cord stimulation (SCS) in the setting of acute aSAH, and to evaluate clinical effects of cervical SCS in a small group of selected aSAH patients. The study was undertaken in preparation for a larger scale randomized trial of SCS for prevention of cerebral arterial vasospasm following aSAH.

Materials and Methods

A single arm non-randomized prospective study of cervical SCS in aSAH patients was performed in University of Illinois at Chicago. Standard percutaneous 8-contact SCS electrodes were implanted under an Investigational Device Exemption protocol in 12 consecutive patients that satisfied strict inclusion criteria: age 18-65, angiography-confirmed aSAH within 3 days prior to implantation, Hunt/Hess (H&H) grade 2-4, Fischer grade 2-4, no history of previous cervical spine surgery, ability to consent the patient/family. All electrodes were inserted using percutaneous approach under general anesthesia immediately upon completion of the definitive surgical or endovascular procedure to secure the ruptured aneurysm. SCS was delivered for the soonest of either 14 consecutive days or until the patient's discharge. Daily vital signs, laboratory values, transcranial Doppler, computed tomography and angiography results were recorded along with the information on presence of clinical vasospasm and all interventions aimed at vasospasm prevention and treatment.

Results

Mean age of implanted patients was 49 years (range – 27-62), average H&H grade – 2.9, average Fisher grade – 3.3. Three had aneurysms coiled and 9 – clipped. One patient developed multisystem failure and expired on post-operative day 11. In two patients, electrode was inadvertently pulled out on days 7 and 13 after the implantation. No complications were related to the electrode insertion or SCS during the study. Angiographic vasospasm was observed in 6 out of 12 patients, and clinical vasospasm – in 2/12; no patient suffered any vasospasm-related neurological complication. Both incidences were smaller than predicted based on the patients' Fisher and H&H grades.

Conclusion

This is the first North American study of SCS for aSAH-related vasospasm prevention; it conclusively showed both safety and feasibility of this promising invasive treatment approach. Our data indicate that despite high acuity level in aSAH patients, general severity of medical condition, impaired level of consciousness, frequent patient re-positioning, need in multiple tests

and variety of monitors, SCS electrodes may be safely implanted and maintained for the two-week period. Further data analysis and additional studies are needed to evaluate its therapeutic benefit.

References

Goellner E., Slavin K.V. Cervical spinal cord stimulation may prevent cerebral vasospasm by modulating sympathetic activity of the superior cervical ganglion at lower cervical spinal level. *Med Hypotheses*, 2009, Epub ahead of print.

Learning Objectives:

Upon completion of this educational activity, attendee will be able to:

1. Describe use of spinal cord stimulation in treatment of cerebral vasospasm
2. Discuss potential benefits of neuromodulation in improvement of outcome following SAH
3. Understand issues on feasibility of spinal cord stimulation in intensive care settings

September 12, 2009

#15

Abstract Title:

Recognition and successful management of spontaneous speech-induced cough following vagus nerve stimulator (VNS) implantation in a patient with drug-resistant depression: case report and literature review

Primary Presenter:

Alexander G. Weil, MD

Primary Presenter Institution:

Department of Surgery, Division of Neurosurgery, Notre Dame Hospital, University of Montreal, Montreal, Qc, Canada

Co-presenter(s):

2. Alain Bouthillier, MD, MSc, 3. Louis Guertin, MD, 4. Elise Lagarde, RN, 5. Veronique Debaumes, MSc, 6. Jean-Guy Villemure, MD, 7. Paul Lespérance, MD, MSc

Co-presenter(s) institutions:

Alain Bouthillier, MD and Jean-Guy Villemure, MD

Department of Surgery, Division of Neurosurgery, Notre Dame Hospital, University of Montreal, Montreal, Qc, Canada

Louis Guertin, MD

Department of Surgery, Division of Otolaryngology, Notre Dame Hospital, University of Montreal, Montreal, Qc, Canada

Elise Lagarde, RN, Veronique Debaumes, MSc, and Paul L'Espérance, MD, MSc

Department of Psychiatry, Notre Dame Hospital, University of Montreal, Montreal, Qc, Canada

Presenting author's full street address and e-mail address:

1230 rue St Timothée, apt 3

Montreal, Qc, Canada

H2L 3N6

Email: alexander.weil@umontreal.ca

Introduction

Vagus nerve stimulation (VNS) therapy is an effective adjunctive treatment for chronic or recurrent treatment-resistant depression in adults. It is administered through an implanted pulse generator that delivers programmed electrical pulses through an implanted lead to the left vagus nerve. Although it is a safe procedure, increasing output current is associated with increased side effects, including voice alteration, cough, a feeling of throat tightening, and dyspnea. We report the first case, to our knowledge, of a spontaneous dry cough induced by speech and mild exercise following implantation of a VNS, in OFF mode. We describe the possible pathophysiology and successful management of this rare adverse effect.

Materials and Methods

Case Report and review of the literature

Results

A 56-year-old male patient was implanted with a vagus nerve stimulator (VNS) for medically refractory recurrent major depression as part of a type II affective bipolar disorder. Seven days after undergoing VNS implantation, with the VNS in OFF mode, the patient developed dry cough induced by speech and mild exercise, significantly affecting his quality of life, limiting initiation of speech, and delayed commencement of vagus nerve stimulation therapy by 4 weeks. Upon evaluation, neurological examination was normal and flexible laryngoscopy revealed no vocal cord paralysis. The patient was diagnosed with speech-induced dry cough secondary to VNS implantation and was treated with short-course of chlorpromazine(5 days) and NSAIDS. The patient witnessed 50% and 75% reduction in cough frequency after 24h hours and 1 week of treatment, respectively. This decreased the threshold for cough-induction and allowed VN stimulation to be commenced 6 weeks after implantation.

Conclusion

Spontaneous speech-induced dry cough is a rare complication of VNS that may affect quality of life and delay stimulation treatment. Medical therapy, particularly chlorpromazine, may be effective at reducing cough threshold and frequency, allowing stimulation to be performed.

References

1. Shafique S, Dalsing MC. Vagus Nerve Stimulation for Treatment of Drug-Resistant Epilepsy and Depression. *Perspect Vasc Surg Endocasc Ther* 2006. 18;323-327
2. Nemeroff, Mayberg HS, Krahl SE, McNamara J, Frazer A, Henry TR, et al. VNS Therapy in Treatment-Resistant Depression: Clinical Evidence and Putative Neurobiological Mechanisms. *Neuropsychopharmacology* 2006. 31: 1345-1355

Acknowledgements

This work did not receive any funding

Learning Objectives:

1. Describe speaking-induced cough as a potential complication of VNS implantation
2. Describe the effective treatment of cough secondary to VNS implantation and its rationale
3. Propose hypothesis on the pathophysiology of speech-induced dry cough following VNS implantation

September 12, 2009

#16

Abstract Title: Evaluation of Parkinsons disease information available on the internet for french speaking patients

Primary Presenter: Alexander G. Weil, MD

Primary Presenter Institution: Department of Surgery, Division of Neurosurgery, Notre Dame Hospital, University of Montreal, Montreal, Qc, Canada

Co-presenter(s):

2. Donia Mahjoub, MD

3. Paule Bonaventure

4. Jacques Jamart

5. Tatiana Witjas, MD

6. Marc Leveque, MD

Co-presenter(s) institutions: Alexander G. Weil, Paule bonaventure

Department of Surgery, Division of Neurosurgery, Notre Dame Hospital, University of Montreal, Montreal, Qc, Canada

Jacques Jamart, Biostatistics service, Cliniques Universitaire UCL, Mont-godinne, Belgique

Donia Mahjoub, Tatiana Witjas, Marc Leveque, Pole Neurosciences CHU de la Timone, Marseille, France

Presenting author's full street address and e-mail address:

1230 rue St Timothée, appt 3

Montreal, Qc, Canada

H2L 3N6

Email: alexander.weil@umontreal.ca

Introduction

The internet has become an important ressource for patients and provides information that often leads them to make decisions concerning disease management. Little is known about the type and quality of medical information, especially for Parkinsons disease and deep brain stimulation. The purpose of this study was to evaluate the quality of these sites based on their accessibility, comprehensibility and accuracy

Materials and Methods

Six keywords were entered into 2 different search engines. Keywords employed included: Parkinson's disease, akinesia, dopaminergic agonist, essential tremor, dyskinesia, and deep brain stimulation. For each keyword, the first 50 websites were reviewed by two neurologists using the DISCERN evaluation tool.

Results

Six-hundred websites were evaluated for quality and comprehensiveness by two independent neurologists. These websites were evaluated for comprehensibility and quality, as well as multiple variables susceptible to affect quality (bibliography, recent update, author, affiliation, financing).

Conclusion

The results of this study confirmed that searching for medical information on the internet is time consuming and dissapointing. The immense quantity and heterogeneous information available on the internet must incite neurosurgeons and neurologists to become aware of the content on the internet available to patients and efforts must be made, particularly by professional societies, to address this issue.

Learning Objectives:

- 1) Describe the content and evaluate the quality of information for Parkinsons disease available on the internet for French speaking patients
- 2) Identify factors that can indicate better website quality
- 3) Develop the proficiency and tools necessary (e.g. a list of good quality websites) to guide the patient in his online search for information on Parkinsons disease and deep brain stimulation

September 12, 2009

#17

Abstract Title: Burst stimulation of the auditory cortex for noise-like tinnitus

Primary Presenter: Dirk De Ridder, MD, PhD

Primary Presenter Institution: BRAI²N & Dept. of Neurosurgery, University Hospital Antwerp, Belgium

Co-presenter(s): Vanneste S, MSc, MA; van der Loo E, MSc, Plazier M, MD; Menovsky T, MD, PhD; Vancamp T, BA; Van de Heyning P, MD, PhD

Co-presenter(s): BRAI²N & Dept. of Neurosurgery, University Hospital Antwerp, Belgium

Presenting author's full street address and e-mail address: Wilrijkstraat 10, 2650 Edegem, Belgium. Dirk.de.ridder@uza.be

Introduction

Tinnitus is an auditory phantom percept related to tonic and burst hyperactivity of the auditory system. Two parallel pathways supply auditory information to the cerebral cortex: the tonotopically organised lemniscal system, and the non-tonotopic extralemniscal system, firing in tonic mode and burst mode respectively. Electrical cortex stimulation is a method capable of modulating activity of the human cortex, by delivering stimuli in a tonic or burst way. Burst firing is shown to be more powerful in activating the cerebral cortex than tonic firing and bursts may activate neurons that are not activated by tonic firing.

Materials and Methods

Five patients with an implanted electrode on the auditory cortex were asked to rate their tinnitus distress and intensity on a Visual Analogue Scale before and after tonic and burst stimulation. All patients presented both pure tone and narrow band noise tinnitus.

Results

Results show a significant better suppression for narrow band noise tinnitus with burst stimulation in comparison to tonic stimulation, $Z=2.02$, $p=.043$. For pure tone tinnitus no difference is found between burst or tonic stimulation, $Z=0$, ns.

Conclusion

Based on the hypothesis that narrow band/white noise is the result of hyperactivity in the non-tonotopic system, we suggest that burst stimulation modulates the extralemniscal system and lemniscal system and tonic stimulation only the lemniscal system.

Acknowledgements

The authors thank SJM for their support

Learning Objectives:

1. Tinnitus can sometimes be treated by auditory cortex stimulation
2. Noise-like tinnitus responds better to burst stimulation
3. burst stimulation might preferentially modulate the extralemniscal system

September 12, 2009

#18

Abstract Title: Surgically implanted electrodes of the auditory cortex as a treatment for tinnitus: a review of 40 patients

Primary Presenter: Dirk De Ridder, MD, PhD

Primary Presenter Institution: BRAI²N & Dept. of Neurosurgery, University Hospital Antwerp, Belgium

Co-presenter(s): Vanneste S, MSc, MA; van der Loo E, MSc, Plazier M, MD; Menovsky T, MD, PhD; Vancamp T, BA; Van de Heyning P, MD, PhD

Co-presenter(s): BRAI²N & Dept. of Neurosurgery, University Hospital Antwerp, Belgium

Presenting author's full street address and e-mail address: Wilrijkstraat 10, 2650 Edegem, Belgium. Dirk.de.ridder@uza.be

Introduction

Any lesion along the auditory tract, interfering with its ascending or descending pathways can generate tinnitus. Tinnitus can be considered a phantom sound caused by auditory cortex hyperactivity, which can be visualized using functional neuroimaging techniques. This visualized area of hyperactivity can be used as a target for modulating associated abnormal neuronal activity.

Methods

Forty patients are selected for implantation of an extradural auditory cortex electrode, contralateral to the side where the tinnitus is perceived. Selection criteria are intractable unilateral tinnitus with twice >50% suppression on transcranial magnetic stimulation (tms) in a placebo controlled way on 2 separate days after exclusion of all treatable causes. A frequency specific fmri is performed, matched to the tinnitus frequency and incorporated in a neuronavigation machine to localize the area where the electrode is implanted.

Results

In general a significant difference can be found on the VAS intensity preoperative ($M = 7.98$, $SD = 2.53$) in comparison to the VAS scale postoperative with stimulation ($M = 3.35$, $SD = 2.81$), $t(38) = 9.41$, $p < .001$. Furthermore a positive correlation can be found between VAS preoperative and postoperative, $r = .34$, $p < .05$, indicating that patients with a lower score on the preoperative VAS intensity are better helped with auditory cortex stimulation than patients with a higher score on the preoperative VAS intensity.

A closer look to the data indicate that tinnitus can be suppressed in 25% of patients for > 80%, in an additional 50% for 50% on average and in 25% not at all. There is no correlation with tinnitus duration. Noise-like tinnitus is more difficult to suppress.

Conclusion

Recent magnetoencephalography and eeg data that the tinnitus intensity is correlated to gamma band activity of the contralateral auditory cortex. Auditory cortex stimulation attempts to suppress this hyperactivity.

Even though all patients responded to TMS 25% still fail to respond to the implanted electrode. EEG studies comparing the failures to the responders demonstrate that activity differences in the left parahippocampal area might differentiate the two groups: $t(9) = 1.98; p < .05$. The preliminary results of the first implantations suggest that auditory cortex stimulation in carefully selected patients can improve tinnitus.

Acknowledgements

The authors thank SJM for their support

Learning Objectives:

1. auditory cortex stimulation can suppress tinnitus
2. 25% are non responders even if TMS can suppress tinnitus
3. non-responders differ in their parahippocampal activity

September 12, 2009

#19

Abstract Title:

Long-term Results of Combination Treatment with Stereotactic P-32 Brachytherapy and Gamma Knife for Craniopharyngioma

Primary Presenter:

YU Xin, Professor
Navy General Hospital
Beijing China
Email: yuxin37@263.net

Introduction

To analyze the long-term follow-up data and to assess the efficacy and safety of combination of stereotactic intracavitary irradiation and Gamma Knife for the treatment of relapsing and postoperative residual craniopharyngioma.

Materials and Methods

Sixty-seven of 95 consecutive patients with craniopharyngiomas treated with combination treatment from Oct. 1996 to Dec. 2003 were selected for retrospective analysis. There were 39 males and 28 females, aged 7 to 70 years (mean, 31.5 years). 35 were further treated by general radiotherapy. All the surgical procedures were done under local anesthesia with Leksell stereotactic system. Enhanced MRI scanning were done, and thereafter two procedures were performed in accordance with the patients' conditions. In 55 patients, Gamma Knife surgery were done in the solid part of the tumors, and then stereotactic cystic fluid aspiration and intracavitary irradiation in the cystic part. In the remaining 12 patients, the cyst were treated with stereotactic intracavitary irradiation for the huge cysts firstly, and following new MRI scanning and Gamma Knife surgery were done.

Results

There was no severe complications and operative death postoperatively. The follow up time was 5 to 12 years, with an average of 8.6 years in 67 patients. The tumor response rate for solid part cyst part and mixed tumor were 83.3%, 90.9% and 89.6%, respectively.

Conclusion

Combination of intracavitary irradiation and Gamma Knife surgery can control the tumors successfully, and it is highly safe and effective in the treatment of relapsing and postoperative residual craniopharyngiomas.

References

1. Chung WY, Pan HC, Guo WY, et al. Protection of visual pathway in gamma knife radiosurgery for craniopharyngiomas. *Stereotact-Funct-Neurosurg.* 1998; 70(Suppl 1):139-151
2. Plowman PN, Wraith C, Royle N, et al. Stereotactic radiosurgery. Craniopharyngioma: durable complete imaging responses and indications for treatment. *British Journal of Neurosurgery* 1999;13(4):352-358
3. Szeifert GT, Julow J, Slowik F, et al. Pathological changes in cystic craniopharyngiomas following intracavitary 90yttrium treatment. *Acta-Neurochir-Wien.* 1990;102(1-2):14-18
4. Inore HK, Kohga H, Kakegawa T, et al. Radiosensitive craniopharyngiomas: the role of radiosurgery. *Acta-Neurochir-Suppl-Wien.* 1994;62:43-46
5. Lunsford LD, Pollock BE, Kondziolka DS, et al. Stereotactic options in the management of craniopharyngioma. *Pediatr-Neurosurg.* 1994;21(Suppl 1):90-97

Learning Objectives:

1. Craniopharyngioma
2. Brachytherapy and Gamma Knife
3. Long-term Results

September 12, 2009

#20

Abstract Title:

Clinical Application of Combination of Surgical Operation for Treatment of Frontal Lobe Epilepsy

Primary Presenter:

LIU Zonghui, Professor
Navy General Hospital
Beijing China
Email: yuxin37@263.net

Introduction

To evaluate the efficiency and safety of surgical operation for treatment of medical intractable frontal lobe epilepsy.

Materials and Methods

Between January 1996 and January 2004, 80 operations such as epileptogenic focus resection and multiple subpial transection (MST) or anterior two-thirds corpus callosotomy were performed for frontal lobe epilepsy. They consisted of 56 males and 24 females, with age ranging from 17 to 66 years (mean 35 years). Of them, 37 cases had generalized seizures, 23 absence and generalized seizures and 20 partial seizures and torsional or rotating seizures. According to the preoperative EEG, CT, MRI, SPECT, PET, Locating measures combined with electrocorticography (ECoG) detection during operation. All operations were performed with operative microscope. The operation would be terminated when the epileptic waves in lesion area were completely disappeared during monitoring with ECoG.

Results

Short-term effective control of seizures were in all patients postoperatively. There is no operative death and sever complication. The follow-up periods were from 1 to 8 years (mean 5 years). 69 patients were seizurs-free, 8 had a $\geq 75\%$ significant reduction , 2 had a $\geq 50\%$ reduction or a change from severe type to moderate type, poor in 1 patient.

Conclusion

The results indicate: the epileptogenic focus resection combined MST or combined two-third conpus callosotomy is an effective and safe approach of the surgical treatment for frontal lobe epilepsy.

References

1. Chauvel P: The frontal lobe seizures and epilepsies: *Epilepsia* 38(6)2-3, 1997.
2. Shimizu, H: Surgical treatment of frontal lobe epilipsy *Epilepsia* 38(6)54-57, 1997.
3. Crespel A, Baldy-Moulinier, M, and Coubes P: The Relationship Between Sleep and Epilepsy in Frontal and Temporal lobe Epilepsies: Practical and Physiopathologic considerations *Epilepsia* 39(2)150-157, 1998.
4. Luders HO, Harold H, Morris III: Frontal lobe Epilepsies: *Epilepsy Surgery* PP185-195. Raven press .Ltd New York, 1992.
5. Mihara, T, Tottori T, Matsuda K et al: Analysis of Seizure Manifestations of pure Frontal lobe origin *Epilepsia* 38(6)42-47, 1997.
6. Behrens E, Schramm J, Zentner J and Kpnig R: Surgical and neurological complications in a series of 708 epilepsy surgery procedures *Neurosurgery* 41(1) 1-10, 1997
7. Aso, K, Watanabe, K, Negoro, T, and Nakashima, S: Frontal lobe Epilepsy of childhood onset *Epilepsia* 38(6)40-41, 1997.

Learning Objectives:

1. Frontal Lobe Epilepsy
2. Surgical Operation

September 12, 2009

#21

Abstract Title: Transcranial direct current stimulation for tinnitus: a preliminary study on 418 tinnitus patients.

Primary Presenter: Sven Vanneste, Msc , Ma

Primary Presenter Institution: BRAI²N & Dept. of Neurosurgery, University Hospital Antwerp, Belgium

Co-presenter(s): Plazier M, MD; Ost J, RN; De Ridder, D, MD, PhD

Co-presenter(s) Institution: BRAI²N & Dept. of Neurosurgery, University Hospital Antwerp, Belgium

Presenting author's full street address and e-mail address: Wilrijkstraat 10, 2650 Edegem, Belgium. sven.vanneste@ua.ac.be

Introduction

Tinnitus is considered as an auditory phantom percept. with a prevalence of 5-15%., 2,4 % of the population is severely affected by it. Preliminary evidence indicates that transcranial direct current stimulation (tDCS) of the temporo-parietal area might reduce on tinnitus. Recent tDCS studies of the prefrontal cortex has shown an effect on depression, pain and impulsiveness.

Materials and Methods

A total of 418 tinnitus patients received bifrontal tDCS on dorsolateral prefrontal cortex (anode right, cathode left) for 30 minutes.

Results

Our results show that tDCS has effect on 29.9% of the tinnitus patients. For the responders a reduction was found for both tinnitus-related distress ($p < .05$) and tinnitus intensity ($p < .05$). In addition, it is revealed that the amount of suppression for tinnitus-related distress but not for tinnitus intensity is moderated by an interaction between tinnitus type and tinnitus laterality moderate the effect) ($p < .01$) . For the latter effect it is shown that unilateral pure tone tinnitus is less suppressed than bilateral pure tone as well as unilateral and bilateral narrow band noise. A closer look at the data indicates that the reduced suppression effect for unilateral pure tone tinnitus can mainly be explained by a very limited suppressive effect on right sided tinnitus.

Conclusion

This study supports the involvement of the prefrontal cortex in the pathophysiology of tinnitus. Bifrontal tDCS has a better effect on the tinnitus-related distress probably due to a direct impact on the frontal distress network and secondarily an indirect effect on the tinnitus intensity. These results are promising as a potential treatment for 1/3 of tinnitus patients. A blinded study has been initiated to prove this concept.

Learning Objectives:

- 1 tDCS can be used as a possible treatment for tinnitus
2. Pure tone tinnitus and bilateral tinnitus are better suppressed than narrow band noise and unilateral tinnitus.
3. Bifrontal tDCS has a larger impact on tinnitus-related distress than on tinnitus-intensity

September 12, 2009

#22

Abstract Title: Is Burst stimulation in TMS a potential treatment for tinnitus?

Primary Presenter: Sven Vanneste, Msc , Ma

Primary Presenter Institution: BRAI²N & Dept. of Neurosurgery, University Hospital Antwerp, Belgium

Co-presenter(s): Plazier M, MD; Ost J, RN; De Ridder, D, MD, PhD

Co-presenter(s) Institution: BRAI²N & Dept. of Neurosurgery, University Hospital Antwerp, Belgium

Presenting author's full street address and e-mail address: Wilrijkstraat 10, 2650 Edegem, Belgium. sven.vanneste@ua.ac.be

Introduction

Tinnitus is an auditory phantom percept related to tonic and burst hyperactivity of the auditory system. Two parallel pathways supply auditory information to the cerebral cortex: a tonotopically organized lemniscal system, and a non-tonotopic extralemniscal system, firing in tonic and burst mode respectively. Transcranial magnetic stimulation (TMS) is a non-invasive method capable of modulating activity of the human cortex, by delivering tonic or burst stimuli. It has been shown that burst firing is more powerful in activating the cerebral cortex than tonic firing. However burst TMS has a high inter-individual variability. Three factors, namely tinnitus laterality, tinnitus-related distress and tinnitus duration, might contribute to this large individual variation.

Materials and Methods

The effect of burst TMS on the auditory cortex in 100 male individuals is evaluated, presenting narrow band noise or pure tone tinnitus, unilateral or bilateral tinnitus, and low or high tinnitus-related distress.

Results

Our placebo controlled TMS results show that burst stimulation can suppress tinnitus in 50 % of the patients. Yet, significant difference is noted between narrow band noise and pure tone ($F(1,40) = 5.68, p < .05$). More precisely, the amount of suppression for pure tone tinnitus depends on the laterality in interaction with tinnitus duration ($F(1,17) = 10.42, p < .01$) and not by tinnitus-related distress $F(1,17) = .42, n.s.$

Conclusion

Narrow band noise tinnitus can be suppressed by burst TMS. Pure tone tinnitus suppression on the other hand depends on the tinnitus laterality and duration. While bilateral tinnitus can be easily altered by burst TMS independent of the tinnitus duration, unilateral tinnitus can be suppressed when tinnitus duration is less than 4 years. This might be due to more pronounced degeneration of the lemniscal system in comparison to the extralemniscal system described in deafferentation.

Learning Objectives:

- 1 Burst TMS stimulation can suppress tinnitus both narrow band noise and pure tone tinnitus
2. The amount of suppression for pure tone tinnitus dependent on the laterality and duration of tinnitus
3. Chronic deafferentation of the lemniscal system is more severe than the extralemniscal system.

September 12, 2009

#23

Abstract Title: Effect of STN-DBS on camptocormia accompanied by Parkinson disease

Primary Presenter:

Takashi Asahi, MD, PhD
Toyama, Japan
Takashi-tym@umin.ac.jp

Co-presenter(s):

Yoshiharu Taguchi, MD, PhD., Hideo Hamada, MD, PhD, Nakamasa Hayashi, MD, PhD,
Shunro Endo, MD, PhD, Nobuhiro Dougu, MD, PhD, Shunro Takashima, MD, PhD, Koraro
Tanaka, MD, PhD

Introduction

Few multiple case studies of the effect of deep brain stimulation for camptocormia accompanied by Parkinson disease have been reported. Most of them were improved, however, some were not effective against camptocormia. It was not investigated into what kind of patients would be expected to be improved after DBS. We treated 4 Parkinson patients with camptocormia and evaluated their paraspinal muscle status by computed tomography.

Materials and Methods

The 2 female and 2 male patients were 60-69 years old. The duration of disease from onset to surgery was 7-13 years and the follow-up period was 4-24 months. The electrodes were

implanted bilaterally in the subthalamic nuclei. Pre- and post-operative angle of the trunk, UPDRS, LED were evaluated. Paraspinal computed tomography was performed and evaluated thalacomlumber paraspinal muscle status.

Results

Camptocormia was improved in 3 cases; it was unchanged in 1 case, although other Parkinsonian symptoms improved. The Hounsfield number of the paraspinal muscle in the unimproved case was remarkably smaller than that in the improved group.

Conclusion

here might be a relation between improvement and fat degeneration of paraspinal muscle.

References

- Lepoutre AC, Devos D, Blanchard-Dauphin A, et al. A specific clinical pattern of camptocormia in Parkinson's disease. *J Neurol Neurosurg Psychiatry* 2006;77:1229-1234.
- Ashour R, Jankovic J. Joint and skeletal deformities in Parkinson's disease, multiple system atrophy, and progressive supranuclear palsy. *Mov Disord* 2006;4:1856-1863
- Umemura A, Toyoda T, Okita K, et al. effect of deep brain stimulation for postural abnormality in Parkinson's disease. *Funct Neurosurg* 2008;47:119-122.(in Japanese)
- Hellmann MA, Djaldetti R, Israel Z, Melamed E, et al. Effect of deep brain subthalamic stimulation on camptocormia and postural abnormalities in idiopathic Parkinson's disease. *Mov Disord* 2006;21:2008-2010
- Yamada K, Goto S, Matsuzaki K, et al. Alleviation of camptocormia by bilateral subthalamic nucleus stimulation in a patient with Parkinson's disease. *Parkinson Relat Disord* 2006;12:372-375.
- Micheli F, Cersósimo MG, Piedimonte F. Camptocormia in a patient with Parkinson disease: beneficial effects of pallidal deep brain stimulation. Case report. *J Neurosurg* 2005;103:1081-1083.
- Lang AE, Lozano A, Montgomery E, Duff J, Tasker R, Hutchinson W. Posteroventral medial pallidotomy in advanced Parkinson's disease. *N Engl J Med* 1997;337:1036-1042
- Djaldetti R, Mosberg-Galili R, Sroka H, Merims D, Melamed E. Camptocormia (bent spine) in patients with Parkinson's disease--characterization and possible pathogenesis of an unusual phenomenon. *Mov Disord* 1999;14:443-447
- Wunderlich S, Csoti I, Reiners K et al. Camptocormia in Parkinson's disease mimicked by focal myositis of the paraspinal muscles. *Mov Disord* 2002;17:598-600
- Bonneville F, Bloch F, Kurys E, et al: Camptocormia and Parkinson's disease: MR imaging. *Eur Radiol* 2008;18:1710-1019
- Azher S, Jankovic J, et al: Camptocormia. Pathogenesis, classification, and response to therapy. *Neurology* 65:355-359,2005.
- Bonneville F, Bloch F, Kurys E, et al.: Camptocormia and Parkinson's disease: MR imaging. *Eur Radiol* 18:1710-1019, 2008
- Schäbitz WR, Glatz K, Schuhan C, et al: Severe forward flexion of the trunk in Parkinson's disease: focal myopathy of the paraspinal muscles mimicking camptocormia. *Mov Diord* 18: 408-414,2003
- Tiple D, Fabbrini G, Colosimo C, et al: Camptocormia in Parkinson disease: an epidemiological and clinical study.*J Neurol Neurosurg Psychiatry* 80:145-148, 2009

Learning Objectives:

1. Retrospectively investigate whether STN-DBS is effective in camptocormia accompanied by Parkinson disease.
2. To know what factor is related to ineffectiveness in camptocormia.

September 12, 2009

#23

Abstract Title: Deep Brain Stimulation for Parkinson's Disease Patients without an Adequate Levodopa Response: Alternative Indications

Primary Presenter: Takashi Morishita, M.D.

Primary Presenter Institution: Department of Neurosurgery, University of Florida College of Medicine/Shands Hospital, Movement Disorders Center, McKnight Brain Institute, Gainesville, FL

Co-presenter(s): Kelly D. Foote, M.D.¹, Ihtsham U Haq, M.D.², Pamela Zeilman, A.R.N.P.², Charles E Jacobson B.S.², Michael S. Okun, M.D.^{1,2}

Co-presenter(s):

1. Department of Neurosurgery, University of Florida College of Medicine/Shands Hospital, Movement Disorders Center, McKnight Brain Institute, Gainesville, FL
2. Department of Neurology, University of Florida College of Medicine/Shands Hospital, Movement Disorders Center, McKnight Brain Institute, Gainesville, FL

Presenting author's full street address and e-mail address:

Department of Neurosurgery
100 S. Newell Drive
PO Box 100265
Gainesville, FL, USA 32610-0265
Phone: 352-273-9000
Fax: 352-273-8413
takashi.morishita@neurology.ufl.edu

Background

Currently deep brain stimulation (DBS) is indicated for medication refractory levodopa responsive Parkinson's disease (PD) patients. At most expert institutions, the patients are selected based on the results of levodopa challenge test, and optimal candidates usually have greater than 30% improvement in the motor portion of Unified Parkinson's Disease Rating Scale (UPDRS) following medication administration. There may however be patients who have alternative indications (medication resistant tremor or severe on/off fluctuations). The aim of this study was to examine the outcomes in a cohort of patients with alternative indications for DBS.

Materials and Methods

We queried our institutional review board (IRB) approved DBS database for cases with PD who had DBS but preoperatively possessed a less than 30% improvement on a levodopa challenge test. Patients were drawn from between the dates of July 2002 and March 2009. We reviewed the history (e.g. indication for DBS and brain target) and we compared the preoperative and postoperative UPDRS Part II, Part III, and PDQ-39 scores utilizing a paired student's t-test.

Results

Our database revealed 153 PD DBS patients, and of those 9 had less than a 30% improvement on levodopa challenge test. Unilateral globus pallidus interna (GPi) was chosen as a target in two patients with severe dyskinesia and presence of mild cognitive impairment. Unilateral subthalamic nucleus (STN) DBS was performed for severe dyskinesia (n=3), on/off motor fluctuations (n=1) and medication resistant tremor (n=3) patients. Although there was no

significant change pre- to postoperatively in the UPDRS Part III, the UPDRS Part II and PDQ-39 subscores (activities of daily living, emotional, and stigma) improved ($p < 0.05$).

Conclusion

This study highlights cases where a cut-off of 30% on UPDRS may miss patients who may benefit from DBS. Patients with severe dyskinesia, on/off motor fluctuations, and/or medication resistant tremor may have the potential for significant benefits despite UPDRS motor score changes.

Learning Objectives:

1. Selection of potential DBS candidates in Parkinson's disease.
2. Alternative indications for DBS in Parkinson's disease.
3. Target selection (GPi vs STN) in Parkinson's disease.

September 12, 2009

#24

Abstract Title: Dopamine dysregulation syndrome with l-dopa reduction after STN-DBS

Primary Presenter: Chikashi Fukaya

Primary Presenter Institution: Department of Neurological Surgery and Division of Applied System Neuroscience, Nihon University School of Medicine, Tokyo, Japan

Co-presenter(s): Mitsuru Watanabe, Koichiro Sumi, Otaka Toshiharu, Obuchi Toshiki, Kano Toshikazu, Nagaoka Takafumi, Kobayashi Kazutaka, Oshima Hideki, Yamamoto Takamitsu, Yoichi Katayama

Co-presenter(s): Department of Neurological Surgery and Division of Applied System Neuroscience, Nihon University School of Medicine

Presenting author's full street address and e-mail address:

30-1 Oyaguchi Kamimachi, Itabashi-ku, Tokyo 173-8610, Japan
chikashi@med.nihon-u.ac.jp

Introduction

Longstanding exposure to dopaminergic drug may cause a reward system malfunction and provokes DDS (Dopamine dysregulation syndrome) which links sensitization of ventral striatal circuitry. This may manifest as addiction to l-dopa and behavioral disturbances. STN-DBS (subthalamic nucleus – deep brain stimulation) enable us to improve PD (Parkinson's disease) patients' motor symptom and reduce a dose of dopaminergic drug. Significant reduction of dopaminergic drug sometimes elucidated the existence of DDS. Appropriate programming of stimulation parameters and regulation of anti-parkinsonian drugs are important to obtain a good outcome after the surgical procedure. We studied the characteristics and the risk factors of DDS which become dominant after the STN-DBS.

Materials and Methods

Subjects were 95 patients with detailed follow-up more than 6 months who underwent STN-DBS during the period of 2005 to 2008 in our institute. We selected a patient who psychologically resisted the dopaminergic drug reduction after the STN-DBS. Particularly, we made note of the patients manifesting a remarkable pathological feeling and abnormal behavior which associated with l-dopa reduction. We studied the contents of their deviatory behavior, preoperative condition and dose of dopaminergic drug.

Results and Conclusion

Relatively large number of patients experienced dysphoric withdrawal symptoms and 10 patients revealed deviatory behavior accompanied by the reduction of l-dopa dose. The

contents of the deviatory behavior were mainly related to anxiety, depression, anhedonia, and cenesthopathy. In some patients, cenesthopathy occurred as laryngeal abnormal sensation like a sensory apnea. Such symptom was extremely difficult to control by either STN-DBS or medical treatment. Such intractable symptom seems to be relevant to dopamine coupled with substance P, play the important role in laryngeal sensation. According to an analysis of preoperative state of DDS patients, younger patients with high dose l-dopa administration tend to be fall into such pathological condition.

Learning Objectives:

1. Understanding Dopa dysregulation syndrome after STN-DBS
2. Understanding predictive factor of Dopa dysregulation
3. Understanding adverse effect of longstanding exposure to dopaminergic drug

September 12, 2009

#25

Effects of Chronic STN DBS Treatment on Long-duration Response to L-dopa:

Evidence for restoring long-duration response

Chong S. Lee, MD FRCPC¹, Sang Y. Chun, MD², Mi J. Kim, MD¹, Sun J. Chung MD¹, Sung R. Kim RN¹, Myung C Lee¹, MD

¹Institute for Parkinson's Research/ Dept of Neurology, ²Dept of Neurosurgery, Asan Medical Center, University of Ulsan College of Medicine, Seoul Korea

Purpose: To explore the effect of STN DBS on L-dopa response in PD patients

Background: Severe motor fluctuation is the most common reason referring to STN DBS treatment for PD patients. L-dopa response in patients with motor fluctuation is characterized by decreased duration and increased magnitude, caused by loss of long duration response (LDR) leading to more parkinsonism at the off state ("off-parkinsonism") and greater magnitude of short duration response (SDR). STN DBS improves off-parkinsonism, hence, motor fluctuations. Interestingly, the good response to L-dopa seems prerequisite for beneficial outcome from STN DBS for PD patients. Putting together, we postulate that STN DBS may improve motor fluctuations by reversing drug-induced longstanding changes in L-dopa response, in addition to the concurrent effect on off-parkinsonism by neurostimulation.

Methods: Forty nine patients with advanced PD (age: 56.8±7.77; duration: 12.2±4.06 years) underwent bilateral STN DBS. L-dopa test was performed before and 6 months after DBS surgery, using 150% of a single L-dopa equivalent dose that the patient had been taking. Parkinsonism was assessed using UPDRS, serially twice at med-off and -on states before surgery, and at med-off and -on states with DBS-on or DBS-off in 6 months after surgery. The SDR magnitude was expressed as difference from baseline: OFF UPDRS motor scores – ON UPDRS motor scores. OFF UPDRS motor scores and the SDR magnitudes were compared between before and after 6 months' STN DBS treatment. For ANOVA, patients were divided into 3 groups based on OFF UPDRS motor scores before surgery. Data were also analyzed by regression methods.

Results: OFF UPDRS scores were 26.4±4.08, 37.5±2.74, and 50.3±8.86 before surgery (in the group A, B, C respectively; p<0.001). Changes in OFF UPDRS scores over 6 months period were +8.34±2.70, +1.00±9.49, -7.31±14.9 in the group A, B, and C respectively (p=0.002). The reduced amount of OFF UPDRS scores over 6 months period was highly correlated with initial

preop OFF UPDRS scores ($r=0.610$, $p<0.0001$), indicating that the higher the preop UPDRS scores, the greater the reduction of UPDRS scores after 6 months. SDR magnitudes before surgery were 16.9 ± 6.27 , 22.7 ± 7.49 and 29.8 ± 10.7 in the group A, B, and C ($p=0.0003$), with significant correlation between preop OFF UPDRS scores and preop SDR magnitudes ($r=0.672$, $p<0.0001$). As in the case of OFF UPDRS, SDR magnitudes were reduced substantially after 6 months' STN DBS treatment, amounting to 32%, 24%, and 18% reduction in the group A, B, and C respectively, with no significant group differences. The reduced amount of SDR magnitude over 6 months period was highly correlated with initial, preop SDR magnitude ($r=0.626$, $p<0.0001$), indicating that the greater the initial preop SDR magnitude, the greater the reduction of SDR magnitude after 6 months. Initial preop UPDRS scores did not show significant correlations after the correlation with initial preop SDR magnitude was taken into account. Age and duration of PD did not influence significantly any of these correlations.

Conclusions: Our data show that (1) chronic STN DBS treatment improved off-parkinsonism, which was greater as the initial preop off-parkinsonism was worse, and that (2) it reduced magnitude of SDR, which was greater as the initial preop SDR magnitude was higher. To the extent that worsening of off-parkinsonism reflects the loss of LDR to L-dopa in advanced PD, these findings suggest that LDR is induced by drug treatment rather than reflecting loss of dopamine terminals, and that chronic STN DBS may reverse the drug-induced loss of LDR.

September 12, 2009

#26

Abstract Title:

Effect of unilateral stimulation of subthalamic nucleus for Parkinson disease

Primary Presenter:

Yasukazu Kajita M.D.

Primary Presenter Institution:

Department of Neurosurgery, Nagoya University, Postgraduate School of Medicine, Nagoya, Aichi

Co-presenter(s):

- 1) Yoshiki Kanaoke M.D.
- 2) Hirofumi Tanei M.D.
- 3) Daisuke Nakatsubo, M.D.
- 4) Toshihiko Wakabayashi M.D.

Co-presenter(s):

- 1) National Institute for Physiological Science, Okazaki, Aichi
- 2)-4) Department of Neurosurgery, Nagoya University, Postgraduate School of Medicine, Nagoya, Aichi

Presenting author's full street address and e-mail address:

65 Tsurumai Shouwa-ku, Nagoya, 466-8550, Japan
ykajita@med.nagoya-u.ac.jp

Introduction

Bilateral subthalamic nucleus (STN) deep brain stimulation (DBS) is regarded as a standard surgical treatment of severely disabled patients with medically intractable Parkinson disease (PD). However, bilateral surgery is accompanied by the adverse effects including cognitive deficits, depression, and speech disturbances¹. Although unilateral DBS is less aggressive than bilateral surgery, the efficacy of unilateral DBS has not been evaluated in the study of the high number of the patients². We report the effect of unilateral STN DBS at the 6-month follow-up examination in 104 cases with PD.

Materials and Methods

Between January 2001 and September 2008, 104 patients with medically intractable PD underwent unilateral STN DBS. Clinical assessments were performed preoperatively and six months after the last surgery, using the Unified Parkinson's Disease Rating Scale (UPDRS), motor and activity of daily living (ADL) subscores, and Hoehn and Yahr stages.

Results

Mean UPDRS II and III had improved by 42.8% and 23.5% (on stimulation, off therapy), by 11.6% and 4.9% (on stimulation, on therapy). Significant improvement was observed in the hemibody contralateral to surgery (tremor-83%, rigidity-76%, bradykinesia-58% dyskinesia-67%) but not in the ipsilateral (13%). Mean L-dopa daily requirement was reduced from 590.3mg to 460.5mg. Side effects were postoperative hypophonia (4%), nocturnal confusion (3%) and eyelid apraxia (1%).

Conclusion

Unilateral STN DBS are effective and safe treatment for advanced PD and some patients may obtain a substantial benefit with unilateral STN DBS. The patients who are not satisfied with the improvement of axial or ipsilateral symptom may need a second surgery. Unilateral STN DBS may be regarded as the preferred choice for the treatment of some patients including advanced aged or high risked patients.

References

- 1) Hamani C, Richter E, Schwab JM, Lozano AM. Bilateral subthalamic nucleus stimulation for Parkinson disease: A systemic review of the clinical literature. *Neurosurgery* 2005.56:1313-
- 2) Linazasoro G, Blercom NV, Lasa A. Unilateral subthalamic deep brain stimulation in advanced Parkinson's disease. *Movement Disorder* 2003. 18:713-716

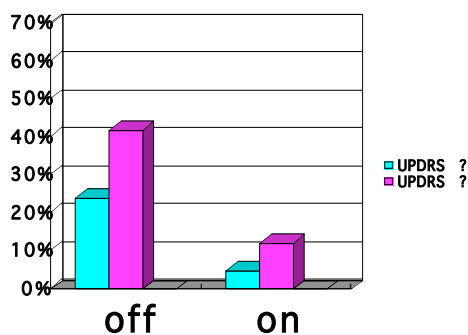


Fig A: Improvement of UPDRS II and III following unilateral STN stimulation

Learning Objectives:

1. Subthalamic deep brain stimulation
2. Parkinson disease
3. Unilateral stimulation

September 12, 2009

#27

Abstract Title: The ratio of STN/SN neuronal activity, a quantitative bio-marker for Parkinson's disease progression

Primary Presenter: C. Chris Kao, MD PhD

Primary Presenter Institution: Department of Neurosurgery, Vanderbilt Medical Center, Nashville, TN 37232 USA

Co-presenter(s): Peter E. Konrad, MD PhD, Joseph Neimat, MD, David Charles, MD and Mike Remple, PhD

Co-presenter(s): Depts. Neurosurgery and Neurology, Vanderbilt Medical Center, Nashville, TN 37232 USA

Presenting author's full street address and e-mail address: Department of Neurosurgery, T-4224 MCN, Nashville, TN 37232-2380 USA, chris.kao@vanderbilt.edu

Introduction Parkinson's disease (PD) is associated with a progressive neuronal loss in the Substantia nigra pars compacta (SNc), reactive subthalamic nucleus (STN) hyperactivity, and its glutamate toxicity onto SNc neurons. The dynamic interaction between STN and SN is likely to parallel the disease progression/neuronal loss. Current report is to study the STN/SN neuronal activity ratio in early and advanced PD patients.

Materials and Methods Eighteen age/sex-matched patients were grouped as PD (early or advanced). Multichannel microelectrode recordings guided DBS implant placement. STN and SN recordings were analyzed offline using the peak root mean square (pRMS) to derive the STN/SN ratio.

Results The STN/SNr (reticular) ratio in the final target tracks were significantly higher in advanced PD patients than those early PD patients (9 pair, 8 male and 1 female) in pool data (LSTN 2.59 ± 0.72 vs. 1.65 ± 0.69 ; RSTN 2.49 ± 0.67 vs. 1.67 ± 0.7 ; $n=9$) and 8/9 in individual data. The SN activity is believed in the reticular part of SN (SNr). Medial to these tracks, the ratio of STN/SNc are bigger than those STN/SNr (10/14) since it were closer to the SNC (neuronal loss area).

Conclusion Both increased STN and decreased SN neuronal activity might correlate with SNc neurodegeneration and PD progression. This ratio holds promise as a functional bio-marker for neuronal loss in PD patients.

Acknowledgements

This study is partially supported by Medtronic grant of Safety and Tolerability of Neurostimulation in Early Stage Parkinson's Disease. PI: P. David Charles

Learning Objectives:

1. To objectively measuring Parkinson's disease progression
2. To measure it functionally using neuronal activity
3. To make this bio-marker clinical relevant

September 12, 2009

#28

Abstract Title:

Effects of electrode implantation angle on thalamic stimulation for treatment of tremor

Primary Presenter:

Kazutaka Kobayashi MD, PhD

Primary Presenter Institution:

Division of Neurosurgery, Department of Neurological Surgery and ²Division of Applied System Neuroscience, Department of Advanced Medical Science, Nihon University School of Medicine, Tokyo, Japan

Co-presenter(s):

Yoichi Katayama MD, PhD^{1,2} Koichiro Sumi MD^{1,2} Toshiharu Otaka MD^{1,2} Toshiki Obuchi MD^{1,2} Toshikazu Kano MD, PhD^{1,2} Takafumi Nagaoka MD, PhD^{1,2} Hideki Oshima MD, PhD^{1,2} Chikashi Fukaya MD, PhD^{1,2} Takamitsu Yamamoto MD, PhD^{1,2} Hideki Atsumi MD, PhD³

Co-presenter(s):

¹Department of Neurological Surgery and ²Division of Applied System Neuroscience, Department of Advanced Medical Science, Nihon University School of Medicine, Tokyo, Japan

³Department of Neurosurgery, Tokai University School of Medicine, Isehara, Kanagawa, Japan

Presenting author's full street address and e-mail address:

Division of Neurosurgery, Department of Neurological Surgery, Nihon University School of Medicine, 30-1 Oyaguchi Kamimachi, Itabashi-ku, Tokyo 173-8610, Japan

kitta@med.nihon-u.ac.jp

Introduction

Many studies have confirmed that deep brain stimulation (DBS) of the thalamus (thalamic DBS) has been an effective treatment for tremor. The optimal target has been commonly accepted to be situated within the ventral thalamus, but a standard trajectory of the DBS electrode has not yet been established. We report a case in which the effects of stimulation of the thalamus on tremor differed depending on the angle of the DBS electrode relative to the anterior commissure (AC)–posterior commissure (PC) line.

Case Report

A 53-year-old man with an eleven-year history of essential tremor was treated with DBS of the thalamus. Intraoperative stimulation with a DBS electrode temporarily inserted at a high angle to the horizontal plane of the AC – PC line to cover only the nucleus ventralis intermedius (Vim) was not effective. In contrast, stimulation with the DBS electrode permanently implanted at a low angle, covering a wide area extending from the nucleus ventralis oralis (Vo) to the Vim, reduced the tremor.

Conclusion

These results suggest that the trajectory of the DBS electrode may be a considerable factor for the implantation of a DBS electrode for tremor therapy

Learning Objectives:

1. Understanding deep brain stimulation for treatment of tremor
2. Understanding technique of electrode implantation for treatment of tremor

September 12, 2009

#29

Title: MOTOR CORTEX STIMULATION (MCS) FOR ADVANCED PARKINSON DISEASE (PD): LONG TERM RESULTS

Primary Presenter: Meglio M, MD

Primary Presenter Institution: Dipartimento di Neuroscienze – Università Cattolica – Roma - Italy

Co-presenter(s): Cioni B, MD, Bentivoglio AR, MD, Conforti G, MS, De Simone C, MD, Daniele A, MD, Piano C, MD, Zinno M, MD

Co-presenter(s) Institution: Dipartimento di Neuroscienze – Università Cattolica – Roma – Italy

Presenting author's full street address and e-mail address:

Neurochirurgia Funzionale e Spinale - Università cattolica – Policlinico Gemelli - Lg Gemelli, 8 – 00168 Roma – Italy mmeiglio@rm.unicatt.it

Introduction: DBS for Parkinson Disease has shown several limitations and contraindications. MCS has been proposed as a possible alternative treatment and the purpose of this study was to test the safety and the long term clinical efficacy of MCS in PD.

Material and method Inclusion criteria: - idiopathic PD of long duration, in the advanced stage, - DBS contraindicated or refused, - signed informed consent. 10 patients were submitted to the implant of epidural electrodes over the motor cortex contralateral to the worst clinical side in 3 cases, and bilateral in the remaining 7. MCS during the first year was contralateral to the worst clinical side (120micros, 80c/s, 3-6V). After 12 months stimulation became bilateral. Clinical assessment at baseline and after 3,6,12,24,36, and 48 months of MCS: -UPDRS, - PDQL, - neuropsychological evaluation, - EEG, - oral medications and adverse events. The data are reported in an intention to treat analysis; Wilcoxon test was used for statistical analysis.

Results A significant improvement compared to preoperative scores was present after 12, 24, 36 and 48 months of MCS in global UPDRS off-med, in UPDRS III off-med (by 25%), in subscores for axial symptoms off-med (by 30%), in UPDRS IV, IN UPDRS II off-med and in PDQL. In each patient the UPDRS III off-med at 24, 36 and 48 months was always lower than at baseline. Drug treatment was decreased by 25%. In all patients, no significant postoperative decline was observed on any cognitive task, including tasks of verbal fluency and abstract reasoning.

No adverse event occurred.

Conclusions: MCS for PD is a low risk surgical procedures; our neuropsychological data suggest that MCS is also safe as concerns cognitive and behavioural morbidity. It is followed by a moderate improvement of motor symptoms, particularly axial symptoms, and by an amelioration of daily living that persist at long term (36 and 48 months).

References:

- ❖ Canavero S, Paolotti R Extradural motor cortex stimulation for advanced Parkinson's disease. *Mov Disord* 2000. 15:169-171
- ❖ Cioni B. Motor cortex stimulation for Parkinson's disease. In: D Sakas, B Simpson, E Krames, eds. *Operative Neuromodulation*. Springer-Verlag; Acta Neurochir Suppl 97/2:233-238, 2007
- ❖ Pagni CA, Altibrandi MG, Bentivoglio AR, Caruso G, Cioni B, Contarino F, et al Extradural motor cortex stimulation for Parkinson's disease: History and first results by the study group of the Italian Neurosurgical Society. *Acta Neurochir*. 2005 (Suppl) 93:113-119

Learning objectives: this paper focuses on the safety and long term clinical efficacy of motor cortex stimulation in Parkinson disease

September 12, 2009

#30

Title: LONG TERM FOLLOW-UP IN VAGAL NERVE STIMULATION FOR DRUG-RESISTANT EPILEPTIC PATIENTS

Primary Presenter: Mario Meglio MD

Primary Presenter Institution: Functional and Spinal Neurosurgery, Catholic University, Rome, Italy

Co-presenters:

F. Fuggetta, F. Papacci, D. Policicchio and G. Colicchio

Co-presenter(s) Institution:

Functional and Spinal Neurosurgery, Catholic University, Rome, Italy

Presenting author's full street address and e-mail address:

Neurochirurgia Funzionale e Spinale – Università Cattolica Largo Agostino Gemelli 8 – 00168 – Rome, ITALY

mmeglio@rm.unicatt.it

Introduction

Aim: to assess the long-term results of vagal nerve stimulation in drug-resistant epileptic patients.

Material and Method

62 drug resistant epileptic patients, excluded from ablative surgery, were submitted to vagal nerve stimulation (1995– 2008).

11 children (6-17 years), 51 adults (18-65 years). The follow-up in years ranges: more than 10 in 8 patients; 5-10 in 9 patients; 1-5 in 23 patients; less than 1 in 8 patients. 13 patients drop-out.

Baseline assessment for three months: seizure diary, antiepileptic drug plasma concentration monitoring. Follow-up consists of ambulatory visit every 6 months during the first year and then every year.

Clinical outcome was determined by comparing the seizure frequency at each follow-up visit with the previous 3 months baseline period. We also considered frequency of cluster and status and an evaluation both from patients and their families of the impact on the patients life.

“Responders” were the patients with a seizure frequency reduction of 50% or more and patients experiencing a subjective improvement in quality of life.

Results

clinical outcome is assessed in 54 patients with more than 1 year of follow-up.

Seizure frequency: after 1 years only 10% of patients are Responders. After 5 years mean seizure frequency reduction 24%, Responders 30%. After 10 years mean seizure frequency reduction 35%, Responders 50%.

The percentage increase of the results of vagal nerve stimulation is related both to the cumulative effect of the stimulation as well as to the drop out of the non Responders patients.

Considering also the perception of quality of life 41 patients (75%) could be considered as Responders.

13 patients drop-out due to inefficacy. Complication: 2 cases of infection; reimplanted.

Conclusion

Our study confirm the long-term efficacy of vagus nerve stimulation on seizure number and global quality of life.

References:

- De Giorgio CM., Schachter SC, Handforth A., Solinsky M., Thompson J., Uthman B, et al. Prospective long term study of vagus nerve stimulation for the treatment of refractory seizures Epilepsia 2000 Sep 41(9):1195-1200
- Di Lazzaro V., Oliviero A., Pilato F., Saturno E., Dileone M., Meglio M., et al. Effect of vagus nerve stimulation on cortical excitability in epileptic patients. Neurology 2004 Jun 22;62(12):2310-2312

Learning objectives: the goal of this presentation is show the effects of chronic vagal nerve stimulation in drug resistant epileptic patients.

September 12, 2009

#31

Abstract Title: Should we go back to Vim thalamic DBS for cases of severe refractory dystonic tremor

Primary Presenter: Takashi Morishita, M.D.

Primary Presenter Institution:

Department of Neurosurgery, University of Florida College of Medicine/Shands Hospital, Movement Disorders Center, McKnight Brain Institute, Gainesville, FL

Co-presenter(s):

Kelly D. Foote, M.D.¹, Ihtsham U Haq, M.D.², Pamela Zeilman, A.R.N.P.², Charles E Jacobson B.S.², Michael S. Okun, M.D.^{1,2}

Co-presenter(s):

1. Department of Neurosurgery, University of Florida College of Medicine/Shands Hospital, Movement Disorders Center, McKnight Brain Institute, Gainesville, FL
2. Department of Neurology, University of Florida College of Medicine/Shands Hospital, Movement Disorders Center, McKnight Brain Institute, Gainesville, FL

Presenting author's full street address and e-mail address:

Department of Neurosurgery, 100 S. Newell Drive.

PO Box 100265, Gainesville, FL, USA 32610-0265

Phone: 352-273-9000

Fax: 352-273-8413

takashi.morishita@neurology.ufl.edu

Introduction

Tremor when presenting with dystonia has been referred to in the literature as "dystonic tremor".

¹ Although recent studies have demonstrated excellent outcomes following deep brain stimulation (DBS) of the internal globus pallidus (GPi) in selected cases, the optimal target for dystonia and dystonic tremor remains unknown. The aim of this study was to determine the efficacy in patients we have treated with ventral intermediate nucleus (Vim) DBS.

Materials and Methods

We queried our IRB approved DBS database for cases of dystonia (n=30) and tremor (n=75), we then identified all cases of dystonic tremor (n=4) who underwent DBS. We reviewed their history and responses to the treatment.

Results

Patient #1 was a 47 year-old woman with primary generalized dystonia associated with severe tremor in her head and in both upper extremities. The patient initially underwent bilateral GPi DBS which failed to suppress the dystonic head and hand tremor. Bilateral Vim DBS was successfully added to address tremor. Patient #2 was a 37 year-old man with a history of developmental delay and dystonic tremor in the left arm. Tremor was successfully captured by a right Vim DBS. Patient #3 was a 71 year-old female with a purported history of essential tremor treated with bilateral Vim DBS at an outside institution. A neurological examination revealed cervical dystonia associated with dystonic tremor in the neck and upper extremities. The dystonic tremor was successfully suppressed by thalamic DBS. Patient #4 was a 35 year-old man with a history of generalized dystonia associated with dystonic tremor in both hands. Bilateral GPi DBS alleviated the dystonic posture and the tremor. In cases #1, 2 and 4, low frequency stimulation was effective for the tremor.

Conclusion

This case series raises the question as to whether we should strongly consider Vim DBS for tremor if it is the major disability for the patient presenting with dystonia. Cases such as #4 however have demonstrated that tremor can be suppressed by GPi DBS in select cases where there is a background of generalized dystonia.

Reference

1. Deuschl G., Bain P., Brin M., and an Ad Hoc Scientific Committee. Consensus Statement of the Movement Disorder Society on Tremor. *Mov Disord* 1998. 13: 2-23.

Learning Objectives:

1. Target selection based on dystonia phenotype
2. Optimal stimulation setting for dystonia

September 12, 2009

#33

Abstract Title: Impact of STN stimulation on young-onset Parkinson's disease.

Primary Presenter:

HIDEKI OSHIMA, M.D., Ph.D.

Primary Presenter Institution:

Nihon University School of Medicine, Tokyo, Japan

Co-presenter(s):

Toshiharu Otaka, M.D., Ph.D., Toshikazu Kano, M.D. Ph.D., Kazutaka Kobayashi, M.D., Ph.D., Yutaka Suzuki, M.D., Ph.D., Chikashi Fukaya, M.D., Ph.D., Takamitsu Yamamoto, M.D., Ph.D., Yoichi Katayama, M.D., Ph.D.

Co-presenter(s):

Nihon University School of Medicine, Tokyo, Japan

Presenting author's full street address and e-mail address:

30-1 Oyaguchi-kamimachi, Itabashi-ku, Tokyo 173-8610, Japan

Email: hoshima@med.nihon-u.ac.jp

Introduction

To clarify the efficacy of subthalamic nucleus (STN) stimulation in young-onset Parkinson's disease (PD), we compared the effects of STN stimulation on the motor symptoms between young-onset PD (YOPD) and late-onset PD (LOPD).

Materials and Methods

We analyzed the effects of STN stimulation on motor function and motor fluctuations in 15 patients with YOPD, and 113 patients with LOPD who underwent STN stimulation during the same period. The Unified Parkinson's Disease Rating Scale (UPDRS) was evaluated during the on-period and off-period, which are defined as the times at which the motor symptoms are the best and worst during the daily active time with sustaining anti-parkinsonian drugs. The dyskinesia severity rating scale (DSRS) was also employed to evaluate the severity of peak-dose dyskinesia. We analyzed the changes in levodopa equivalent dose (LED), motor fluctuation, DSRS and UPDRS part 3 score after STN stimulation, and compared the changes in each score between the two groups (YOPD vs. LOPD).

Results

The LED was reduced, and the on-off motor fluctuation index, dyskinesia rating scale score (on-period), and UPDRS part 3 score (on- and off period) were improved in both the YOPD and LOPD groups. The improvement rates of the UPDRS part 3 scores in both on- and off-period of the YOPD group were superior to those of the LOPD group. The results of multivariate logistic regression analysis demonstrated that YOPD itself is the best responder to STN stimulation.

Conclusion

STN stimulation can reduce the LED and improve motor fluctuation in patients with YOPD. The effects of STN stimulation on the motor symptoms of YOPD patients are superior to those in LOPD. The present findings suggest that YOPD patients suffering from several problems related to pharmacological therapy are probably good candidates for STN stimulation.

Acknowledgements

The present work was supported by a grant from the Ministry of Education, Culture, Sports, Science, and Technology of Japan (Grant No. 18209046).

Learning Objectives:

1. Understand about deep brain stimulation therapy for Parkinson's disease
2. Understand about a clinical feature of young-onset Parkinson's disease

September 12, 2009

#34

Abstract Title: Deteriorative factor of long-term activity of daily living in patients with advanced Parkinson's disease underwent subthalamic nucleus stimulation

Department of neurological surgery division of neurosurgery and

Division of Applied System Neuroscience

Nihon University School of Medicine_Tokyo

Toshiharu Otaka, Mitsuru Watanabe, Takashi Morishita, Koichiro Sumi, Toshiki Obuchi,

Katsunori Shijo, Toshikazu Kano, Takafumi Nagaoka, Kazutaka Kobayashi,

Hideki Oshima, Chikashi Fukaya, Takamitsu Yamamoto, Yoichi Katayama

Objective: Subthalamic nucleus stimulation (STN-DBS) can provide long-term effects for activity of daily living (ADL) in patients with advanced Parkinson's disease (PD) characterized by marked motor fluctuation. However, ADL becomes worse a few years later in some patients underwent STN-DBS whereas their ADL had been independent during early period after DBS surgery. We investigated the factor which deteriorates ADL of those cases.

Methods: Sixty-six patients were underwent bilateral STN-DBS at less than 65 years old between 2001 and 2003. Their Schwab and England (S & E) scale score during on-period were 80 % and more, at 2 weeks after surgery. In seven patients out of these 66 patients, S & E scale (on-period) score became 70 % or less, after more than 1 year from surgery. We investigated those 7 patients, and compared the subscales of UPDRS (on-period) score (rigidity, item 22; akinesia, item 26; freezing, item 14; postural instability, item 30) of them at 2 weeks after surgery with the score when their ADL became worsen and analyzed the factors for deteriorating ADL in PD after STN-DBS.

Results: The score of postural instability and freezing became significantly worsen ($p < 0.05$). There were not significantly difference in the scores of rigidity and akinesia.

Conclusion: Results of present study suggest that the deterioration of postural instability and freezing during on-period are deteriorative factor of long-term ADL in patients with advanced PD after STN-DBS.

September 12, 2009

#35

Abstract Title: Cognitive Outcome of Bilateral Subthalamic Deep Brain Stimulation in Parkinson's Disease With and Without Mild Cognitive Impairment

Primary Presenter: Alexander I. Tröster, Ph.D.

Primary Presenter Institution: Department of Neurology, University of North Carolina School of Medicine, Chapel Hill, North Carolina, USA

Co-presenter(s):

Julie A. Fields, Ph.D.¹

Kelly Lyons, Ph.D.²

Rajesh Pahwa, M.D.²

Steven B. Wilkinson, M.D.²

Co-presenter(s):

¹Mayo Clinic, Rochester, Minnesota, USA

²University of Kansas Medical Center, Kansas City, Kansas, USA

Presenting author's full street address and e-mail address:

Dept. of Neurology, UNC – Chapel Hill (CB 7025)

3128 Physicians' Office Building

170 Manning Drive

Chapel Hill, NC 27599-7025

troster@neurology.unc.edu

Introduction

Subthalamic deep brain stimulation (STN DBS) for Parkinson's disease (PD) has been found to be safe from a cognitive standpoint in a majority of patients. A minority of patients experience cognitive declines, most often in verbal fluency, less often in memory and executive functions.

Declines are typically mild and transient, but in few cases can be more serious and lasting. Risk factors for cognitive declines remain poorly specified but STN DBS is not considered a suitable treatment for PD patients with dementia. Recent identification of Mild Cognitive Impairment (MCI) syndromes (and associated risk for dementia) in PD raises the issue whether neuropsychological outcomes after DBS are poorer in patients with MCI.

Materials and Methods

MCI was retrospectively defined in a group of 24 consecutive bilateral STN DBS patients who had undergone neuropsychological evaluation before and about 3.5 months after DBS. MCI definition was based on scores 1.5 or more SD below normative means on one or more tests of attention, language, visuo-perceptual function, executive function and memory in the absence of dementia. Defining tests were not used as outcome measures.

Results

Of 24 patients, 7 had MCI (1 multiple domain). Groups were comparable at baseline in disease duration and severity, depression and anxiety, and dopaminergic medication dosage. Even on an extensive neuropsychological test battery, PD with MCI showed significantly greater decrement on only a test of spatial memory. Motor outcomes and stimulation parameters were comparable.

Conclusion

Prevalence of MCI in this surgical sample without dementia was comparable to that recently reported in community and tertiary care PD samples. Although the sample size of this study is small, findings suggest that MCI in PD may predispose to poorer cognitive outcome after STN DBS in only a very limited manner and that outcomes in this group may be comparable to those observed in PD patients without MCI.

Learning Objectives:

1. Describe typical cognitive outcomes after subthalamic deep brain stimulation for Parkinson's disease
2. Identify at least two possible risk factors for poor cognitive outcome after subthalamic deep brain stimulation
3. Identify one domain of cognition that may be more affected by subthalamic deep brain stimulation in Parkinson's disease patients with Mild Cognitive Impairment (MCI) than in patients without MCI.

September 12, 2009

#36

Abstract Title:

Deep brain stimulation of the globus pallidus interna improve chorea in a patient with chorea-acanthocytosis

Primary Presenter:

Wei Wang, MD

Place of Employment: Department of Neurosurgery, West China Hospital, Sichuan University, Chengdu Sichuan, P.R.China, 610041

Email: co_60@126.com

Co-presenter(s):

Peng Li, MD, Xing Wang, MD, Qi Zhong, MD, Xin Zhan, MD, YanMing Xu, MD, Ding Lei, MD, Hui-Fang Shang, MD

Co-presenter(s):

Department of Neurosurgery, West China Hospital, Sichuan University, Chengdu, SiChuan, China

Introduction

Chorea-acanthocytosis is a rare autosomal recessive disorder. Up to date, treatment is symptomatic and supportive. Results of few cases treated with deep brain stimulation (DBS) are not consistent.

Materials and Methods

A 39-year-old Chinese man from a consanguineous family developed tic-like orofacial movements, shoulder shrugging, neck stretching and slight gait instability at the age of 17. His symptoms gradually progressed and developed orofacial dyskinesias, lingual dyskinesias and tongue biting at the age of 27. His symptoms were improved by taking tiapride. He developed difficulty in writing, speaking, swallowing and walking since chorea occurred at the age of 36 without improvement with high dose tiapride. An attack of a generalized tonic clonic seizure occurred at the age of 37. His older sister died of similar condition at the age of 40. Laboratory tests was performed.

Results

Acanthocytes (6%) were detected on peripheral blood smear. CPK levels were slight increased. Brain MRI revealed basal ganglia atrophy and abnormal intensity in bilateral putman nucleus. EMG showed neurogenic impairment of bilateral anterior tibialis. No mutation of IT 15 gene was detected to exclude Huntington's disease. Other laboratory tests were performed to exclude other auto-immunological disorders and metabolic disorders. Finally, he was diagnosed as chorea-acanthocytosis and performed surgery treatment. Bilateral Medtronic 3387 electrodes were implanted in the globus pallidus interna_Gpi. His symptoms such as chorea and dystonia were dramatically improved 3 weeks after operation with low-frequency stimulation (40Hz), 3.5v and 60_sec. However, his symptoms were worsening at the condition of high-frequency (130Hz).

Conclusion

Bilateral DBS of the Gpi could improve chorea and dystonia in the patient with chorea-acanthocytosis. However, the benefit effect need further follow up.

Acknowledgements

We thanks the patient to participate the study

References

1. Wihl G, Volkman J, Allert N, Lehrke R, Sturm V, Freund HJ. Deep brain stimulation of the internal pallidum did not improve chorea in a patient with neuro-acanthocytosis. *Mov Disord* 2001;16:572-575.
2. D. Guehl, E. Cuny, F. Tison, A. Benazzouz, E. Bardinet, Y. Sibon, et al. Deep brain pallidal stimulation for movement disorders in neuroacanthocytosis. *Neurology* 2007; 68(9):160-161

Learning Objectives:

1. Treatment of Chorea-acanthocytosis

September 12, 2009

#37

**The Clinical Experience of Adjusting Electrode for Post-DBS in STN Neurosurgery
Department of Zhujiang Hospital of Southern Medical
University, Guangzhou, China_510282**

Shi-zhong ZHANG Wang-ming ZHANG Feng-fei LU

Objective: To explore the experience of adjusting electrode for the post-DBS patients in STN when the curative effect is unsatisfactory due to the poor position.

Method: I summarized 7 cases who were not well controlled or showed significant side effects among 101 cases. First, the position deviation of the electrodes were found by Magnetic Resonance Imaging, then underwent reoperation to adjust pole's position. For some cases, altering electrode position along vertical axis during the operation. Firstly applying C arm X-Ray machine forming laterally cranial position imaging to locate the electrode. Subsequently pull out the electrode or implant wire once again to attain the expected purpose. Especially for those cases altering position toward to STN along vertical axis, It is necessary to pull out the electrode completely. Then secondarily implant the new electrode by MR localization. All the patients implanted the new electrode can use MR to confirm the position in the anatomical Structure.

Result: Among the 7 patients, 5 patients' electrodes were adjusted along vertical axis. 4 cases' electrodes were Under the STN(Unilaterally respectively), the average deviation was 7mm_1 case over the STN, the deviation 10 mm. 2 cases in the direction of Posterior and Intra-STN. All of patients show more curative effect after operation.

Conclusion: After the first DBS in STN for Parkinson's Disease if showing unsatisfactory therapeutic effect or the poor position confirmed by MR. It is possible to attain the Perfect effect through the secondary operation. Especially for some electrodes above the STN, we can utilize the limited rigidity of the electrode to press itself on surface of cranial tissue. At the same time, Effectiveness appears on MR scans with stereotactia frame. therefore, it is also worth popularizing and applying.

September 12, 2009

#38

Effects of thalamic reticular nucleus electrical stimulation in rats in a T-maze perseverative behavior model

Pablo Andrade, MD^{1,2}. José D. Carrillo-Ruiz, MD & PhD^{1,2}. Ylián Ramírez, MD & MSc³. Fiacro Jiménez, MD & PhD^{1,2}.

1. Unit of Functional Neurosurgery, Stereotactic and Radiosurgery, Mexico General Hospital, Mexico City, Mexico.

2. Anáhuac University, School of Medicine and Psychology, Mexico City, Mexico.

3. Research Department, Mexico General Hospital, Mexico City, Mexico.

Introduction.

Obsessive-compulsive disorder has a worldwide prevalence of about 3% of the population (approximately 180 million people). Several authors have published beneficial outcomes of deep brain stimulation in patients with obsessions and compulsions at different targets. One of the most accepted experimental models for OCD in rats is the perseverative behavior in a T-maze, produced by a presynaptic 5-HT agonist effect such as 8-OH-DPAT. Our aim was to evaluate the possible decrease of chemically induced perseverative behavior in rats after electrical stimulation at different frequencies in the thalamic reticular nucleus.

Material and Methods.

Twenty-eight male rats were divided in 4 groups; control, sham, OFF stimulation and ON stimulation (450 μ sec, 1V, 6 and 120Hz). Only control group was submitted to saline solution administration. The rest of the groups underwent the administration of 8-OH-DPAT. All groups were evaluated in a T-maze for perseverative behavior. Intragroup analysis was done through paired T-student and intergroup analysis through an ANOVA test.

Results.

The numbers of choices in the same branch mean for the control group was 1.3 before saline solution and 1.4 post-injection. For the sham group, mean of 1.3 pre 8-OH-DPAT and 3.4 post-administration; for OFF stimulation group 3.3 pre-injection and 1.1 post 8-OH-DPAT; and for ON stimulation 1.1 pre-administration, and in the post-state 1.9 for stimulation at low frequency (6Hz) and 3.4 at high frequency (120Hz). Evident intergroup statistical differences were shown ($p < 0.01$). (Figures 1 & 2).

Conclusions.

The electrical stimulation at low frequency group was the only group that after manipulation with 8-OH-DPAT showed a decrease in perseverative behavior, even close to baseline. Electrical stimulation at high frequency showed the same behavior as the sham and OFF stimulation groups. Considering previous reports, the effect of low frequency stimulation mimics and even surpasses the results obtained by the pharmacological gold standard and chemical lesions in the same nucleus.

Acknowledgments.

This work was supported by the Mexico General Hospital Department of Research funding project number DIC/06/403/04/062.

Figure Legends.

Figure 1. Intragroup behavior differences between the number of perseverations pre and post 8-OH-DPAT evaluation correspondent to each group. Statistical differences were shown in the sham group ($p < 0.05$) and OFF stimulation group ($p < 0.05$).

Figure 2. Intergroup behavior between basal perseverations state from all the animals and after the 8-OH-DPAT administration. Statistical differences between the groups were found ($p = 0.006$).

Learning Objectives:

1. Understand the probable mechanism of action of TRN stimulation inside the obsessive-compulsive disorder circuitry.
2. Incorporate a punctual anatomical structure therapy through surgery inside a pharmacological and neurotransmitter theory.
3. Learn the equivalence of the T-maze model induced by 8-OH-DPAT with OCD patients and its application to surgical stereotactical treatments.

References.

1. [Fernández-Guasti A, Ulloa RE, Nicolini H.](#) Age differences in the sensitivity to clomipramine in an animal model of obsessive-compulsive disorder. *Psychopharmacology*, 2003;166(3):195-2.
2. [Greenberg BD, Malone DA, Friehs GM,](#) Rezai AR, Kubu CS, Malloy PF, et al. Three-year outcomes in deep brain stimulation for highly resistant obsessive-compulsive disorder. *Neuropsychopharmacology*, 2006;31(11):2384-93.
3. Jiménez F, Velasco F, Castro G, Nicolini H, Velasco AL, Salín R, et al. Preliminary study in patients with obsessive compulsive disorder treated with electrical stimulation in the inferior thalamic peduncle. *J Neurosurgery*, In press.
4. Jiménez F, Velasco F, Salin-Pascual R, Hernández JA, Velasco M, Criales JL, et al. A Patient with a Resistant Major Depression Disorder Treated with Deep Brain Stimulation in the Inferior Thalamic Peduncle. *Neurosurgery*, 2005;57:585- 593.
5. [Jiménez F, Velasco F, Salín-Pascual R,](#) Velasco M, Nicolini H, Velasco AL, et al. Neuromodulation of the inferior thalamic peduncle for major depression and obsessive compulsive disorder. *Acta Neurochir Suppl*, 2007;97(Pt 2):393-8.
6. Joel D, Doljansky J, Roz N, Rehavi M. Role of the orbitofrontal cortex and of the serotonergic system in a rat model of obsessive compulsive disorder. *Neuroscience*, 2005;130(1):25-36.
7. [Joel D, Weiner I.](#) The connections of the dopaminergic system with the striatum in rats and primates: an analysis with respect to the functional and compartmental organization of the striatum. *Neuroscience*, 2000;96(3):451-74.
8. [Lipsman N, Neimat JS, Lozano AM.](#) Deep brain stimulation for treatment-refractory obsessive-compulsive disorder: the search for a valid target. *Neurosurgery*, 2007;61(1):1-11.
9. [Nuttin BJ, Gabriëls LA, Cosyns PR,](#) Meyerson BA, Andréewitch S, Sunaert SG, et al. Long-term electrical capsular stimulation in patients with obsessive-compulsive disorder. *Neurosurgery*, 2003;52(6):1263-72.
10. [Velasco F, Velasco M, Jiménez F,](#) Velasco AL, Salin-Pascual R. Neurobiological background for performing surgical intervention in the inferior thalamic peduncle for treatment of major depression disorders. *Neurosurgery*, 2005;57(3):439-48.
11. [Velasco M, Velasco F, Jiménez F,](#) Carrillo-Ruiz JD, Velasco AL, Salín-Pascual R. Electrocortical and behavioral responses elicited by acute electrical stimulation of inferior thalamic peduncle and nucleus reticularis thalami in a patient with major depression disorder. *Clin Neurophysiol*, 2006;117(2):320-7.
12. [Yadin E, Friedman E, Bridger WH.](#) Spontaneous alternation behavior: an animal model for obsessive-compulsive disorder? *Pharmacol Biochem Behav*, 1991;40(2):311-5.

September 12, 2009

#39

Preliminary Results of Deep Brain Stimulation in the Inferior Thalamic Peduncle as Treatment of Obsessive Compulsive Disorder

Fiacro Jiménez MD & PhD^{1,2}, Francisco Velasco MD¹, Pablo Andrade MD², Rafael Salín MD & PhD^{3,4}, Huberto Nicollini MD & PhD⁴, José D. Carrillo MD & PhD^{1,2}, Ylián Ramírez MD¹.

¹ Functional Neurosurgery, Stereotaxy and Radiosurgery Unit of Mexico General Hospital, ² Medicine School of Anahuac University,

³ Mental Health of Faculty of Medicine UNAM, ⁴ Carracci Medical Centre.

Preclinical Results

When non-alternative behavior produced by 8OH-DPAT during T-maze OCD with Wistar rats, the lesion of thalamic reticular nucleus has shown decrease of perseverative behavior similarly

to chlorimipramine effect. Only low frequency (6 Hz) electrical stimulation of the same nucleus has preventive effect over perseverative responses originated by 8OH-DPAT.

Case Report

In 2005, a chronic patient with major depression disorder difficult to treat was implanted in the inferior thalamic peduncle (ITP). She showed a significant decrease of Hamilton Depression Scale without side effects at high frequency (130 Hz) deep brain stimulation (DBS). The patient came back to job and good familiar relationship. After 3 years of DBS she was explanted but she had not a depression relapse.

Objective of Clinical Trial

To evaluate the efficacy and the security of DBS in ITP in OCD difficult to treat.

Patients and Methods

Six patients (1:1 male/female) with OCD (from 9 to 34 years of duration) were bilaterally implanted in ITP. According to Yale-Brown Obsessive Compulsive scale (Y-BOCS) score in base line 3 patients had severe and 3 extreme OCD. They were setting at 5.0 V, 130 Hz and 450 microseconds in bipolar mode during 12 to 48 months. Y-BOCS, Global Assessment Functioning scale (GAF) and side effects check list were applied every 6 months. Drug abuse was present in three of them.

Results

Descriptive Statistics

Period	N	Mean	Std. Deviation	Minimum	Maximum
Base Line	6	35.83	5.879	25	40
Six	6	19.83	5.879	14	29
twelve	6	16.83	4.215	12	22

Test Statistics^b

	six - Y-BOCS score	twelve - Y-BOCS score
Z	-2.214 ^a	-2.226 ^a
Asymp. Sig. (2-tailed)	.027	.026

a. Based on positive ranks.

b. Wilcoxon Signed Ranks Test

Transient anxiety or confusion were presented in four cases, one patient was explanted caused tubercular meningitis and one patient dead by cocaine overdose. There was not change in drug abuse conditions. Best results were showed in patients without co-morbidity.

Conclusion DBS in ITP could be useful to amelioration of OCD symptoms. Best results could be getting in patients without co-morbidity. Anxiety could be different kind of symptoms than OCD.

September 12, 2009

#40

Abstract Title:

Deep brain stimulation for Tourette's syndrome, report of three cases

Primary Presenter:

Takanobu Kaido, MD

Department of Neurosurgery, National Center of Neurology and Psychiatry

Kodaira, Tokyo, Japan

Email: kaido@ncnp.go.jp

Co-presenter(s):

Taisuke Otsuki, MD, Akio Takahashi, MD, Yuu Kaneko, MD

Co-presenter(s):

Place of Employment: Department of Neurosurgery, National Center of Neurology and

Psychiatry City: Kodaira State: Tokyo Country: Japan

Introduction

Patients of intractable Tourette syndrome suffer from frequent severe motor and phonic tics which deteriorate activity of daily life. Recent studies reported that deep brain stimulation was carried out to the patients of severe symptoms with remarkable improvement of symptoms.

Materials and Methods

We performed deep brain stimulation in three cases (1 male, 2 females, 19-21 years old) of medically-intractable Tourette syndrome. Tentative target was bilateral centromedian-parafascicular (CM-Pf) nucleus of thalamus.

Results

All of the patients showed remarkable improvement of tics. The score of Yale global tic severity scale were markedly decreased without any deterioration of recognition or mental state.

Conclusion

Deep brain stimulation of thalamus for Tourette syndrome may be an effective and safe treatment for intractable Tourette syndrome

September 12, 2009

#41

Abstract Title: Ablative Versus Ablative/Stimulating Combined Stereotactic and Functional Neurosurgical Procedures in Anorexia Nervosa- Preliminary Results

Primary Presenter: Hemmings C. Wu, M.D.

Primary Presenter Institution:

Department of Neurosurgery, Ruijin Hospital, Shanghai Jiaotong University

Presenting author's full street address and e-mail address:

Room 2501, 185 Zhong-Hua Road, Shanghai, China, 200010

hemmingscwu@gmail.com

Ablative Versus Ablative/Stimulating Combined Stereotactic and Functional Neurosurgical Procedures in Anorexia Nervosa- Preliminary Results

*Hemmings C. Wu, Yixin Pan, Feng Li, Dayuan Xu, Dianyou Li, Shikun Zhan, Bomin Sun
Department of Functional Neurosurgery, Shanghai Jiaotong University Ruijin Hospital,
Shanghai, China*

Background: Anorexia nervosa, characterized by ego-syntonic self-starvation, denial of illness, and ambivalence towards treatment, is a spreading psychiatric and behavioral disorder among young Chinese females. Despite psychopharmacological advances, it is thought to have the

highest mortality rate of any psychiatric disorder due to multiple psychiatric comorbidities, and high refractory rate and relapses. Our center began applying stereotactic and functional neurosurgical approach to medically refractory anorectic patients in 2006.

Objective: To investigate and analyze the short-term efficacy of ablative and ablative/stimulating combined functional neurosurgical procedures in anorexia nervosa.

Design and Method: Non-controlled follow-up trial of 41 patients who underwent stereotactic functional neurosurgical procedures within the last 3 years (thermocapsulotomy or thermocapsulotomy/nucleus-accumbens-deep-brain-stimulation combined) is conducted. We evaluate the clinical outcomes according to the 4 major components of diagnostic criteria of anorexia nervosa: perception of obesity, body image and self-esteem, body mass index, and hormone disturbance (amenorrhea). The Eating Attitude Test (EAT-26) is deployed as the major scale to assess anorectic symptoms.

Results and Conclusions: We observe substantial increase in body mass index, as more than 80% of the patients are no longer underweight during follow-up. Obesity raised our concern, however, as approximately one third of the patients are overweight at follow-up. Menstrual cycle recovered in those who have reached and maintained at or above normal body weight. Nevertheless, fear of obesity and distortion of body image and self-esteem does not completely resolve, even when body weight returns to normal range. Adverse effects, especially cognitive and behavioral disorder and personality change were reported in many, and they can result devastation as they interferes patients' family relations and social functions. Comparison between ablative and ablative/stimulating combined procedures will be addressed.

Learning Objectives: Surgical outcome in different subsets of anorexia nervosa will be discussed. The attendees will share the latest functional neurosurgical results in anorexia nervosa from our group, and they are welcome to debate the question of whether stimulation is necessary/redundant after ablative procedures, or vice versa.

September 12, 2009

#41

Abstract Title:

Long-term result of deep brain stimulation for pain relief

Primary Presenter:

Hyung-seok Kim, MD,

Primary Presenter Institution:

Dept. of Neurosurgery, St. Vincent's Hospital, The Catholic Univerisit of Korea, Suwon, Republic of Korea

Presenting author's full street address and e-mail address:

93-6, Chi-dong, Paldal-gu, Suwon, Gyeonggi-do, Republic of Korea, 442-723

Dept. of Neurosurgery, St. Vincent's Hospital, nshs@catholic.ac.kr

Introduction

Chronic intractable pain syndromes have been treated by electrical stimulation of deep brain structures for the decades. There is a debate regarding the longterm effectiveness of deep brain stimulation for the treatment of chronic pain. We report our long-term result of sensory thalamic nucleus/periventricular gray matter/ hypothalamic deep brain stimulation.

Materials and Methods

Since May 2003, We performed deep brain stimulation for patients with chronic intractable pain. Inclusion criterias were: chronic pain duration > at least 6 mo, visual analogue scales(VAS) >7/10, identifiable anatomic cause of pain, medically intractable pain. Preoperative mean VAS was about 7.5/10. The result was assessed with VAS and patients assessment of pain relief (percentage pain relief (PPR)).

Results

DBS was effective in 9 out of 12 patients in initial trial, then chronic stimulation was given. At 6 months follow-up, the mean PPR at 6 months was about 58.75 %. However, the analgesic efficacy declined after 6-12 months in most cases. At long-term follow-up (32 months), DBS was effective in only 3 out of 9 patient (33 %) with mean PPR of 56.6 %. The analgesic effect was lost in 6 chronic stimulation patients with less than 30 % pain relief.

Conclusion

In our results, the analgesic effect of DBS was not maintained for more than initial 6-12 months after surgery in more than half of patients. The longterm effect was observed in one thirds of intractable pain. A more sophisticated trial and study of DBS for pain relief should be warranted.

Acknowledgements

No financial support or relationship in this paper.

Learning Objectives:

1. Chronic intractable pain syndromes
2. Deep brain stimulation

September 12, 2009

#42

Abstract Title: Long-term Results of Stereotactic Thermocoagulation Treatment Obsessive-Compulsive Disorder

Primary Presenter:

Xin-Min XU, MD
The Neurosurgery Department of 261 Hospital of PLA
Beijing, China
Email: xxmsw261@sina.com

Co-presenter(s):

1. Name: Jie YAN Credentials: MD
2. Name: Hong LI Credentials: MD
3. Name: Ji-Xin ZHANG Credentials: MD
4. Name: Ming BA Credentials: MD

Co-presenter(s):

1. Place of Employment: The Neurosurgery Department of 261 Hospital of PLA. City: Bei Jing
Country:CHINA

Introduction

The authors sought to determine the long-term outcome of subjects with severe and refractory obsessive-compulsive disorder (OCD) who had undergone operation of stereotactic thermocoagulation surgery from the 2003s. Special emphasis was given to the analysis of lesion target sites.

Materials and Methods

9 OCD subjects who had undergone operation of the stereotactic thermocoagulation. Every patients had been evaluation by psychiatrists according to clinical symptoms of them. Anterior capsulotomy was basal target sites to treated OCD, if patients had combined another mental symptoms such as aggressiveness, depression and anxiety symptoms. The nucleus of amygdala or/and subcaudate tracts would be selected as lesion targets to add.

Results

In the majority of our subjects obsessive-compulsive symptoms were greatly improved after surgery and so was social adjustment. Improvement of more than 50% on the Yale-Brown Obsessive Compulsive Scale was found for 89% of the subjects.

Conclusion

Stereotactic thermocoagulation surgery is a effective method to treat OCD. But it is important that how did selected perfect targets to destroyed. In spite of anterior capsulotomy was basal target sites to treat OCD, but still needed another targets to be added as accompanying relative mental symptoms of the OCD patients. Because the OCD patients may be showed different additional symptoms such as aggressiveness, depression and anxiety symptoms excepted behavior of the OCD.

References

Moon-Chan KIM, Tae-Kyu LEE, Chang-Rak CHOI. Review of Long-term Results of Stereotactic Psychosurgery. *Neurol Med Chir(Tokyo)* 42,365-371,2002.

Learning Objectives:

1. psychosurgery
2. Neurosurgery

September 12, 2009

#43

Abstract Title: Treating Parkinsonism Using Spinal Cord Stimulation

Ahmed A. Elborn, MD*; Nesreen N. Suwan, MD.

*Pain center of excellence, Department of anesthesiology and Neurology
Adventist Hinsdale hospital

Hinsdale IL. 60521

Primary Presenter: Ahmed A Elborn M.D.

Board certified Anesthesiologist Pain specialist

Medical director of Adventist Hinsdale hospital pain center of excellence

Primary Presenter Institution : Adventist Hinsdale Hospital , Hinsdale ILL 60521

Co-presenter(s): Nesreen N Suwan M.D.

Board certified Pain specialist , Neurologist

Director of Headache section , pain center of excellence Adventist Hinsdale hospital.

Co-presenter(s): Adventist Hinsdale Hospital , Pain Center of Excellence , Hinsdale , IL 60521.

Presenting author's full street address and e-mail address:

505 MID WEST CLUB PARKWAY
OAK BROOK IL 60523.
AHMED2407@aol.com

Introduction

Parkinsonism (also known as Parkinson's syndrome, atypical Parkinson's or secondary Parkinson's) is a neurological syndrome characterized by tremors, hypokinesia, rigidity, and postural instability the underlying cause are numerous and the diagnosis can be complex. The most common cause of Parkinsonism is Parkinson's disease, which is a neurodegenerative disease affecting the brain and impairs the motor skill, speech, and other functions. It belongs to a group of conditions called movement disorders which affect the central as well as the peripheral nervous system presented by tremors Parkinson's disease resulted from decrease stimulation of the motor cortex by the basal ganglia normally caused by the insufficient formation and action of dopamine which is produced in the dopaminergic neurons of the brain. Secondary symptoms may include high level of cognitive dysfunction and subtle language problems.

Parkinson's disease is a chronic and progressive disease that requires broad based management including patient and family education, support group services, general wellness maintenance, physiotherapy, exercise and nutrition. At present there is no cure for Parkinson's disease, but medications or surgery can provide initial relief from symptoms. The most widely used form of medication is L-dopa which has been developed in 1960's and has a remarkable effectiveness against P.D.tremors and other Parkinsonism symptoms. Over time these responses to levodopa was waning and unexpected adverse events from long term treatment become apparent. Surgery was once a common practice but after the discovery of levodopa surgery was restricted to only few cases. And advanced surgical treatment has been developed primarily in response to failure of medical therapy to provide a long term relief.

Deep brain stimulation is presently the most used surgical means of treatment it is not well understood how deep brain stimulation exert its therapeutic effect. Motor cortex stimulation for Parkinsonism also is still under trials as the initial reports showed that the improvement of different symptoms was variable and unpredictable, even though was very cost effective. Other surgical interventions include surgical lesion of the subthalamic nucleus and of the internal segment of globus pallidus, known as thalamotomy, and pallidotomy.

Methods

We report four cases of patients, who suffered from chronic neuropathic pain as well as Parkinsonism tremor .these patients were treated with spinal cord stimulation for their chronic neuropathic pain.

Case Report 1

A 67-year-old woman presented with chronic neuropathic pain in her neck, upper extremities, lower back, and lower extremities. The patient was involved in a motor vehicle accident in 1968 in which she suffered a spinal fracture and also developed an epidural hematoma. She had decompression surgery around the time of the accident, and she subsequently developed chronic pain. She had additional surgeries after the accident to remove scar tissue and to treat her chronic pain, including a spinal fusion and a discectomy.

Some years after her accident, she developed Parkinsonism symptoms (shuffling, bradykinesia, rigidity, and tremor), which were more prominent on the right. The patient tried several

medications for her tremor, but none were efficacious. Her tremor symptoms were attributed to her spinal injury. Her Parkinsonism symptoms ultimately progressed, and the patient was dependent on a motorized wheelchair for the 12 years prior to presentation. The patient also suffered from photophobia, and she tended to wear sunglasses when inside as well as outside. At the time of her initial evaluation, the patient's medications included Valium, Synthroid, Benadryl, MS-Contin, and Simvastatin.

In December 2007 the patient was implanted with bilateral SCS leads for a trial of SCS for the treatment of her chronic lower leg and back pain, with the electrodes placed at the level of T7. The stimulation frequency was 40 Hz, the pulse width was 370 microseconds, and the pulse amplitude ranged from 0.6 to 2.8 mA. The patient reported that her pain as measured by a visual analog scale (VAS) decreased from 10 (maximum) to 2. The patient reported that her gait symptoms improved by 60-70% as well. The patient indicated that she could more easily ambulate with simply the aid of a cane. In March 2008, a permanent SCS device was implanted, again with the dual leads placed at the level of T7. On follow-up, the patient's lower extremity pain was well-controlled with her SCS system and with Ultram.

The patient continued to suffer from chronic neck pain and bilateral upper extremity pain, which were due to her prior motor vehicle accident as well as to spondylosis, degenerative disc disease, and cervical radiculopathy. In May 2008 the patient was implanted with bilateral SCS leads for a trial of SCS for the treatment of her chronic upper extremity and neck pain, with the electrodes placed at the level of C2. The stimulation frequency was 50-60 Hz, the pulse width was 190-300 microseconds, and the pulse amplitude on ranged from 0.1 to 1.0 mA.

With cervical SCS, the patient reported that her pain as measured by VAS decreased to 0. The patient's Parkinson's symptoms were almost completely relieved by SCS. Her right upper extremity tremor as well as her rigidity and bradykinesia were decreased nearly 100% when stimulation was activated. In June 2008, a permanent SCS device was implanted, again with dual leads placed at the level of C2, and the patient had a response that was essentially the same as that seen with the trial leads. Additionally, the patient's photophobia significantly resolved, so that the patient no longer requires sunglasses when indoors. The patient has now taken up painting, which she was unable to pursue previously due to her disabling tremor.

Case Report 2

A 43-year-old woman presented with chronic neuropathic pain in her neck and upper extremities proximal to her elbows. She indicated that her neck would feel progressively tighter throughout the day, making it difficult to hold her head up by the end of the day. She also suffered from chronic nausea. The patient fell down a flight of stairs at age 5, which caused head and neck trauma. The patient fell again at age 27, again suffering head trauma. The patient indicated that her neuropathic pain was ultimately caused by these falls.

The patient noted a tremor at age 33, and she was diagnosed with Parkinson's disease at age 35. Her Parkinson's symptoms included both functional and resting tremors with bradykinesia, mild shuffling gait, rigidity. The patient also appeared to suffer tremor in her abdominal region.

The patient underwent an MRI of her brain and spine, which revealed multiple lesions in her white matter, most prominent in her left parietal lobe and right cerebral white matter. The radiologist indicated that these lesions were consistent with prior trauma as well as possibly with multiple sclerosis. The MRI also revealed an arachnoid cyst in her left cerebellar hemisphere as well as degenerative disc disease at L4/5 and L5/S1. The patient also underwent an EMG, which was significant for a C5/6 radiculopathy, a right ulnar neuropathy, and bilateral carpal

tunnel syndrome. The patient's medications included Cinemet and Azilect for Parkinson's disease, metoprolol for hypertension, meclizine for nausea, and paroxetine for depression.

The patient was initially treated with an epidural corticosteroid injection at C5/6, with some relief for only a brief period. In November 2008 the patient was implanted with bilateral SCS leads for a trial of SCS for the treatment of her chronic neck and upper extremity pain, with the electrodes placed at the level of C2. The stimulation frequency was 40 Hz, the pulse width was 500 microseconds, and the pulse amplitude ranged from 0.3 to 1.1 mA.

The patient reported that her pain as measured by VAS decreased from 8 or 9 to 2. The patient also reported significant relief from her symptoms of Parkinson's disease. Her tremor largely disappeared in her legs, arms, and abdomen. Her rigidity was dramatically decreased, including her neck stiffness. Her shuffling gait was significantly improved, and her posture was also improved relative to her stooping posture at baseline. On follow-up, the patient also reported that her Parkinson's disease medications seemed to be more effective, and she noticed some improvement in her masked facies. The patient felt that her sleep had significantly improved.

The temporary trial leads were removed within a week of placement and activation of stimulation. The patient's pain symptoms returned immediately, while her Parkinson's disease symptoms returned more gradually over a 2-day period.

In December 2008, a permanent SCS device was implanted, again with the dual leads placed at the level of C2. The stimulation parameters were similar to those used in the temporary trial. On follow-up, the patient reported a VAS of 2 one week after surgery and a VAS of 0 one month after surgery. The patient also reported significant improvement in her Parkinson's disease symptoms, similar to the improvement seen in the temporary trial. The patient also reported that her depression had improved.

Case Report 3

A 52-year-old woman presented with chronic neuropathic pain in her neck and upper extremities as well as in the back of her head, along with some numbness in her hands. The patient also suffered from tremor in her upper extremities. Her chronic pain and tremor symptoms began in her early 20's. The patient indicated that her pain and tremor grew worse on exertion. The patient has no family history of tremor. The patient had a discectomy and a cervical fusion of C3/4/5 performed at age 51 to treat her chronic neck and upper extremity pain. She subsequently developed weakness and worsening of tremor in her right upper extremity. A few months later she also had a fusion of L5/S1. The patient also suffered from migraine, blurred vision, and vertigo and she had a prior diagnosis of fibromyalgia.

A prior MRI showed small ischemic changes in the cerebral cortex, including the right lateral ventricle and left midparietal subcortical white matter in the motor area. An EMG was significant for right-sided carpal tunnel syndrome with bilateral ulnar neuropathy and S1 bilateral radiculopathy. The patient admitted that she was previously addicted to alcohol and narcotics but was in recovery after treatment. The patient's medications included pregabalin, duloxetine, and trazodone.

The patient was initially treated with two injections of epidural corticosteroids at L5/S1. After each of the injections, the patient had approximately 65% pain relief for a brief duration. In July 2008 the patient was implanted with bilateral SCS leads for a trial of SCS for the treatment of her chronic neck and upper extremity pain, with the electrodes placed at the level of C2. The

stimulation frequency was 70 Hz, the pulse width was 550 microseconds, and the pulse amplitude ranged up to 3.1 mA.

On follow-up the next day, the patient indicated that she had 100% pain relief. Additionally, her tremors were eliminated. Additionally, the patient claimed improvement in her blurred vision. When the temporary trial leads were subsequently removed, the pain symptoms returned immediately, while the tremor symptoms gradually returned over a 1-week period. The patient was implanted with a permanent SCS system 2 weeks after the trial, with the electrodes also placed at the level of C2. The patient's pain relief was similar to that reported in the trial, and her tremor also resolved with the activation of the permanent implant.

Case Report 4

A 53-year-old woman presented with chronic neuropathic pain in her neck, upper extremities, lower back, and lower extremities, with a VAS of 9. The patient was diagnosed with Parkinson's disease at age 46, and she had tremor of her upper extremities as well as rigidity, bradykinesia, and a shuffling gait. She had weakness and atrophy in her lower extremities, and she had weakness in her right hand. The patient reported that she was unable to write, drink coffee, or tie her shoes. The patient's medications included Cinemet, Requip, and a Neupro patch for Parkinson's disease, Wellbutrin, Effexor, and Ambien CR.

An MRI revealed minor disc herniation at C3/4 and C6/7. It also revealed disc herniation at T7/8, spinal stenosis at L3/4, disc herniation at L4/5, and severe stenosis at L4/L5. An EMG showed a C6 radiculopathy as well as mild carpal tunnel syndrome, which was more pronounced on the right. It also showed a right peroneal neuropathy at the knee and an L5/S1 radiculopathy on the left. The patient did not have any previous surgeries for treatment of her chronic pain.

The patient was treated with an injection of epidural corticosteroids, with an improvement in VAS from 9 to 6. In September 2008 the patient was implanted with bilateral SCS leads for a trial of SCS for the treatment of her chronic neck and upper extremity pain, with the electrodes placed at the level of C2. The stimulation frequency was 40 Hz, the pulse width was 380-600 microseconds, and the pulse amplitude ranged from 0.9 to 3.6 mA.

During the trial, the patient reported 100% improvement in upper extremity pain. Additionally, she had nearly complete resolution of her tremor, rigidity, and bradykinesia. The patient was able to halve her required dose of her Parkinson's disease medications. The patient was implanted with a permanent SCS system a month after the trial, with the electrodes also placed at the level of C2. The patient's pain relief in her neck and upper extremities was nearly 100%. She still had some pain in her leg, with a VAS of 4. Her tremor was 80% resolved with the activation of the permanent implant.

RESULTS

As previously presented, the patients with chronic neuropathic pain in adjunct with parkinsonism symptoms, have been treated with spinal cord stimulation, whether in the cervical region or in the thoracic region, there was an apparent resolution of their tremors both at rest and movement, with reversal of bradykinesia and improvement in their gait as well as excellent relief of neuropathic pain associated with the affected parts.

Discussion

Symptoms of Parkinsonism have been known and treated since medieval times most notably by AVERROES, however it was not formally recognized and its symptoms were not documented

until 1817 in AN ESSAY ON THE SHAKING PALSY by the British physician JAMES PARKINSON.

The underlying biochemical changes in the brain were identified in the 1950's due to largely to the work of Swedish scientist ARVID CARLSSON who later went on to win Nobel prize. L-dopa entered clinical practice in 1967 and the first large study reporting improvements in patients with Parkinson's disease, resulted from treatment with L-dopa was published in 1968. Surgical interventions involved thalamotomy and pallidotomy were an option for resistant to treat cases; they were very invasive, not cost-effective and risky.

Recently DBS showed a promising therapeutics effect, how it exert this is a matter of controversy for the following reasons; first because of the heterogeneity of the brain tissue it is unclear which circuit elements are responsible for the therapeutic effects.

Second HFS is intrinsically a complicated manipulation because target neurons can respond with increased, decreased or mixed temporal patterns of activity as a result the magnitude and even the sign of the target cell responses DBS are unknown.

Finally it is difficult to assess the net outcome of DBS on over all activity in the target cells and region, because electrical stimulation creates artifacts that prevent direct observation of local circuit's responses during HFS itself. DBS is not cost-effective, invasive and recent reports showed cognitive side effects such as impulsivity.

Motor cortex stimulation for Parkinson's disease was reported in 2002 as may represent cost-effective alternative to DBS. Pagni promoted an Italian multicenter study and June 2005 the results in the first 29 cases were reported. Any symptoms of PD could be modulated by MCS but improvement of different symptoms was variable and unpredictable and with some patients being unresponsive. L-dopa induced dyskinesia, painful dystonia, and motor fluctuations were satisfactorily controlled. Currently under investigation is gene therapy, using a non-infectious virus to shuttle a gene into a part of the brain called the subthalamic nucleus. The gene used leads to the production of enzyme called glutamic acid decarboxylase (GAD), which catalyses the production of neurotransmitter called GABA which acts as a direct inhibitor on the overactive cells in the (STN). GDNF (glial derived neurotrophic factor) implanted catheters via a series of biochemical reactions (GDNF) stimulate the formation of L-dopa. GDNF therapy still in development. Stem cell implantation, genetically engineered to produce dopamine-producing cells. These could not constitute cures because they do not address the considerable loss of activity of the dopaminergic neurons. Initial results have been unsatisfactory with patients still remaining their drugs and symptoms. Neuroprotective treatments are the forefront of PD research, but still under clinical scrutiny. Neural transplantation with dopamine producing cells transplant failed to show an improvement in the quality of life although some significant clinical improvement were seen in patients below the age of 60. A significant problem was the excess release of dopamine by the transplanted tissue, leading to dystonias. In our discovery, we found that, spinal cord stimulation demonstrated significant efficacy for the treatment of Parkinsonism tremor as well as chronic neuropathic pain in 4 patients who suffered from both. The level of invasiveness and complexity of the surgery for SCS is substantially less than that of the other surgical options for tremor, lesioning and DBS, MCS, stem cell therapy, gene therapy, and neural transplantation. These cases suggest a promising alternative therapy for tremor patients. As since 1817 till now all modalities for treatment of Parkinsonism were directed towards the brain, considering the fact the path physiology of the disease was in the basal ganglia of the brain. But it was never addressed before as to direct the treatment towards the spinal cord as manifested by our work with four cases reported. The way how the spinal cord

stimulation may work was suggested by electrophysiological data from animal work by Romulo Fuentes, et al. *science* 323, 1578(2009). Our theory suggest that SCS will block the abnormal oscillatory circuits at the level of spinal cords which depend on sensory inputs and play a role in the pathogenesis of tremors. SCS will enhance the negative feedback loop which will block the central oscillatory circuits and prevent the generation of tremors. Lastly, also spinal cord stimulation will enhance the renshaw inhibitory cell effect and modulate the function of motor unit to prevent synchronization that will initiate tremors.

CONCLUSION

Spinal cord stimulation demonstrated significantly efficacy for the treatment of tremor as well as chronic neuropathic pain in 4 patients who suffered from both. The level of invasiveness and complexity of the surgery for SCS is substantially less than that of the other surgical options for tremor, lesioning and DBS. These cases suggest a promising alternative therapy for tremor patients. Additional studies are required to demonstrate the broader applicability of this therapy in patients who are suffering from tremor but not chronic pain.

References

- 1) Fuentes R, Peterson P, Siesser WB, Caron MG, Nicoletis MA. Spinal cord stimulation restores locomotion in animal models of Parkinson's disease. *Science*. 2009 Mar 20; 323(5921):1578-82.
- 2) Andreani J. CM MD, Guma C MD. CAECIF-Buenos Aires-Argentina. FESnet 2002 abstract submission.
Lateral cord stimulation stimulation (LCS) to relieve spasticity. Experimental protocol and results.
- 3) Bloedel JR, Ebner TJ, Godersky JC, et al. physiological mechanisms underlying the effects of cerebellar stimulation. In Davis R, Bloedel JR, Boca Raton, FL, USA: CRC Press: 1984
- 4) M. Karimi; N. Golchin; S.D. Tabbal; T. Hershey; T.O. Videen; J. Wu; J.W.M. Usche; F.J. Revilla; J.M. Hartlein; A.R. Wernle.
Sub thalamic Nucleus Stimulation-induced Regional Blood Flow Responses Correlate with Improvement of Motor Signs in Parkinson Disease 10/20/2008 *Brain j*.
- 5) Dirk Rasche, M.D.¹; Patricia C. Rinaldi, Ph.D.²; Ronald F. Young, M.D.³; Volker M. Tronnier, M.D., Ph.D.¹ Deep Brain Stimulation for the Treatment of Various Chronic Pain Syndromes 05/02/2007 Neurosurgical Focus.
- 6) P David Charles; Chandler E Gill; Thomas L Davis; Peter E Konrad; Alim-Louis Benabid Is Deep brain Stimulation Neuroprotective If Applied Early In The Course Of PD? Nature Clinical Practice Neurology.
- 7). Surgical Treatment of Parkinson Disease, Michele Tagliati, MD, Division Chief of Movement Disorders, Associate Professor, Department of Neurology, Mount Sinai School of Medicine. Ron L Alterman, MD, Associate Professor of Neurosurgery, Mount Sinai School of Medicine; Consulting Surgeon, Department of Neurosurgery, Mount Sinai School of Medicine, Elmhurst Hospital, and Walter Reed Army Medical Center; Jay Shils, PhD, Director of Intraoperative Monitoring, Assistant Professor of Neurosurgery, Neurosurgery, Lahey Clinic
- 8) Deep Brain Stimulation Dramatically Improves Advanced Parkinson's Disease Symptoms *N Engl J Med*. 2006; 355:896-908.
- 9) Alterman RL, Sterio D, Beric A, Kelly PJ. Microelectrode recording during posteroventral pallidotomy: impact on target selection and complications. *Neurosurgery*. Feb 1999;44(2):315-21; discussion 321-3.
- 10) Anderson VC, Burchiel KJ, Hogarth P, et al. Pallidal vs subthalamic nucleus deep brain stimulation in Parkinson disease. *Arch Neurol*. Apr 2005;62(4):554-60.
- 11) Bejjani B, Damier P, Arnulf I, et al. Pallidal stimulation for Parkinson's disease. Two targets? *Neurology*. Dec 1997; 49(6):1564-9.

- 12) Jankovic J. Motor fluctuations and dyskinesias in Parkinson's disease: clinical manifestations. *Move Disord.* 2005; 20 Suppl 11:S11-6.
- 13) Pahwa R, Factor SA, Lyons KE, et al. Practice Parameter: treatment of Parkinson disease with motor fluctuations and dyskinesia (an evidence-based review): report of the Quality Standards Subcommittee of the American Academy of Neurology. *Neurology.* Apr 11 2006; 66(7):983-95.
- 14) Deep-brain stimulation of the subthalamic nucleus or the pars interna of the globus pallidus in Parkinson's disease. *N Engl J Med.* Sep 27 2001; 345(13):956-63.
- 15) Soulas T, Gurruchaga JM, Palfi S, Cesaro P, Nguyen JP, Fénelon G. Attempted and completed suicides after subthalamic nucleus stimulation for Parkinson's disease J Neurol Neurosurg Psychiatry. 2008 Aug; 79(8):952-4. Epub 2008 Apr 1
- 16) Jankovic J (April 2008). "Parkinson's disease: clinical features and diagnosis". *J. Neurosurg. Psychiatry.* 79 (4): 368–76.
- 17) "Parkinson's Disease Mechanism Discovered," HHMI Research News June 22, 2008
- 18) Physiological and pathological tremors and rhythmic central motor control. J.H.McA and C.D. Marsden human movement balance unit, institute of neurology, london, UK.
- 19) Kaplitt MG, Feigin A, Tang C, Fitzsimons HL, Mattis P, Lawlor PA, Bland RJ, Young D, Strybing K, Eidelberg D, Durrleman MJ (2007). "Safety and tolerability of gene therapy with an adeno-associated virus (AAV) borne GAD gene for Parkinson's disease: an open label, phase I trial". *Lancet* 369 (9579): 2097–105. doi:10.1016/S0140-6736(07)60982-9..
- 20) Elbe R. physiologic and essential tremor. *Neurology* 1986; 36:225-31.

Learning Objectives:

- 1.-pathophysiology of tremor
- 2.-Treatment options available for parkinsonism
3. Breakthrough discovery for treating parkinsonism

September 12, 2009

#44

Abstract Title: Motor cortex stimulation in rat Parkinsonian model (Preliminary Report)

Primary Presenter: Seong-Keun Moon, M.D, Ph.D.

Primary Presenter Institution: Department of Neurosurgery, Wonkwang University School of Medicine, Iksan, South Korea

Co-presenter(s):

Jung-Ok Lee, M.Sc.^a, Yong-Il Shin, M.D., Ph.D.^b, Hyo-Joon Kim, M.D.^a, Hyung-Ihl Kim, M.D., Ph.D.^a

Co-presenter(s):

^a Department of Neurosurgery, Presbyterian Medical Center, Jeonju, South Korea.

^b Department of Physical Medicine and Rehabilitation, Wonkwang University School of Medicine, Iksan, South Korea

Presenting author's full street address and e-mail address:

Department of Neurosurgery, Wonkwang University School of Medicine
344-2 Shinyong-dong, Iksan, Jeonbuk 570-749, Republic of Korea

moonsk@wonkwang.ac.kr

Introduction

Recent clinical trials using motor cortex stimulation in the Parkinsonian patients showed the conflicting results. This indicates that more diverse parameters are needed to be tested with more delineation of action mechanism in the animal Parkinsonian models. We studied effect of motor cortex stimulation with different parameters to determine better strategy in rat Parkinsonian model

Materials and Methods

Rats model of Parkinsonism were made by lesioning of unilateral medial forebrain bundle with 6-hydroxydopamine (6-OHDA) and stimulating electrode was implanted on the motor cortex. After 2 weeks of recovery, movement threshold was measured in each rat with brief electrical stimulation. Rotational behavior was induced by injecting apomorphine and concurrently half threshold cortical stimulation (130 Hz, 150 μ sec) was delivered with different mode of stimulation: anodal, cathodal, and biphasic stimulation. Stimulation pattern was further subdivided into 'continuous' and 'intermittent' depending on the duration of stimulation. Stimulation lasted 60 minutes from induction of rotation in each rat.

Results

Intermittent and continuous biphasic stimulation group showed the significant reduction of rotational behavior compared with control group (<0.05). In contrast, anodal and cathodal stimulation did not show the significant reduction of rotation.

Conclusion

Intermittent and biphasic stimulation on the motor cortex is a good strategy to reduce the rotational behavior in rat Parkinsonian model.

September 12, 2009

#45

Abstract Title: Long Term High Frequency Stimulation of Subthalamic Nucleus Increases Dopamine in the Corpus Striatum of Hemiparkinsonian Rhesus Monkey

Primary Presenter: Xiao-ping Zhou, Professor
Department of Neurosurgery, Changhai Hospital
Shanghai PR, China
Email: zhouxp@yaho.com.cn

Co-presenter(s):

1. Name: Xiao-wu Hu, Credentials: Professor
2. Name: Xu-dong Zhao Credentials: Assistant Professor

Co-presenter(s):

1. Department of Neurosurgery, Changhai Hospital City: Shanghai State: Shanghai
Country: PR, China

Introduction

The mechanism of subthalamic nucleus(STN) high frequency stimulation(HFS) for Parkinson disease(PD) still remains elusive. We hypothesize that the level of dopamine(DA) and it's metabolites in the corpus striatum were increased after long term STN HFS. The aim of this study was to examine the level of DA and it's metabolites in the extracellular space of corpus striatum of hemiparkinson monkeys before and after long term STN HFS.

Materials and Methods

Six rhesus monkeys were assigned randomly to two groups: the control group (n=2) and the experiment group (n=4). MPTP induced hemiparkinsonian rhesus monkeys with STN HFS were successfully prepared for the subsequent microdialysis sessions. Collecting dialysates of extracellular space in corpus striatum before turning on the pulse generator, and then collecting dialysates at 8 hour, 1 week, 1 month, 2 month and 8 month after STN HFS. DA and its metabolites were determined by high performance liquid chromatography and electrochemical detection (HPLC-ECD).

Results

After HFS, PD symptoms of monkeys significantly improved. Rotation evoked by APO disappeared immediately after pulse generator turned on. The levels of DA and its metabolites in putamen and caudate nucleus of electrode side both increased significantly at different time point after stimulation compared to prestimulation.

Conclusion

STN HFS significantly improved symptoms of hemiparkinsonian rhesus monkey, which mechanism might be the increase of the release of dopamine and /or its metabolites in corpus striatum.

September 12, 2009

#46

Abstract Title:

Accuracy of electrode placement after subthalamic deep brain stimulation in patients with Parkinson's disease: electrode position analysis with preoperative and postoperative MRI merging technique.

Primary Presenter:

Won Seok Chang, M.D.

Primary Presenter Institution:

Yonsei University, College of medicine, Department of neurosurgery, Seoul, Korea

Co-presenter(s):

Hae Yoo Kim, M.D., Young Seok Park, M.D., Eun Jeong Kwon, R.N., Jin Woo Chang, M.D.,Ph.D.

Co-presenter(s):

Yonsei University, College of medicine, Department of neurosurgery, Seoul, Korea

Presenting author's full street address and e-mail address:

Yonsei University, College of medicine, Department of neurosurgery, Shin-Chon Dong 134 Seo-Dae-Mun Gu, Seoul, Korea. 120-752. E-mail:Changws0716@yuhs.ac

Introduction

Chronic high frequency deep brain stimulation of the subthalamic nucleus (STN) has often been used in the treatment of advanced Parkinson's disease (PD). Although, for accurate positioning of electrode in STN, stereotactic procedures are commonly used, this procedures also have the potential of electrode position error due to brain shifting, instrumental error, error caused by imaging distortion, and errors by each procedural step. We analyzed difference of planned

electrode placement and actual electrode placement after STN DBS with preoperative and postoperative MRI merging technique and try to know if microelectrode recording (MER) data would be mismatched with planned electrode position, what should we do to correct the electrode position error.

Materials and Methods

Total 30 patients with advanced PD were underwent bilateral STN DBS from Aug. 2006 to Dec. 2008. Among them, 7 patients were excluded due to intolerance to taking MRI, or being unable to receive surgery under local anesthesia, which is essential for microelectrode recording. Remained 23 patients (10 male and 13 female) were enrolled in this study. Mean age at surgery were 57 years old (29-70) and mean preoperative unified Parkinson's disease rating scale(UPDRS) part III of drug off-on stage were 42.46(22-62) and 16.1(2-29).

Results

Total Mean actual position error was 1.19 mm (0.3-3.5). Mean difference between planned length and actual length in STN was 0.88 mm (-1.3-3.8). Mean lateral distance error was 0.92mm (0-2.9) and mean AP distance error was 0.55 mm (0-1.7). AP distance error was smaller than lateral distance error, statistically ($p=0.01$). Correlation analysis showed that only length of planned electrode length in STN was positive relationship ($p=0.033$) and other values, AP error, lateral error, and actual error, were not correlated with actual electrode length in STN ($p>0.05$).

Conclusion

Accurate position of electrode in DBS surgery is one of the key points of successful surgical outcome. We used matching the preoperatively planned trajectory and intra-operative findings of MER and microstimulation. Verification was performed with pre- and postoperative MRI merging technique. By these methods, we found that accuracy of Leksell G frame based STN DBS is acceptable if surgeon is careful of CSF leakage and brain shifting by shortening of surgery time and technique for preventing CSF leakage, if surgeon verify instruments in detail. In conclusion, error is still occurred during stereotactic surgery whether it is large or small. Despite usually this position error is acceptable, efforts for minimizing error and developing new technology for accurate electrode positioning will promise better outcome of STN DBS..

References

1. Baunez C, Humby T, Eagle D, Ryan L, Dunnett S, Robbins T: Effects of STN lesions on simple vs choice reaction time tasks in the rat: preserved motor readiness, but impaired response selection. *European Journal of Neuroscience* 13:1609, 2001.
2. Baunez C, Nieoullon A, Amalric M: In a rat model of parkinsonism, lesions of the subthalamic nucleus reverse increases of reaction time but induce a dramatic premature responding deficit. *Journal of Neuroscience* 15:6531-6541, 1995.
3. Baunez C, Robbins T: Bilateral lesions of the subthalamic nucleus induce multiple deficits in an attentional task in rats. *European Journal of Neuroscience* 9:2086-2099, 1997.
4. Bucholz R, Yeh D, Trobaugh J, McDurmont L, Sturm C, Baumann C, Henderson J, Levy A, Kessman P: The correction of stereotactic inaccuracy caused by brain shift using an intraoperative ultrasound device. *Lecture notes in computer science*:459-466, 1997.
5. Feroli P, Franzini A, Marras C, Maccagnano E, D'Incerti L, Broggi G: A simple method to assess accuracy of deep brain stimulation electrode placement: pre-operative stereotactic CT+ postoperative MR image fusion. *Stereotact Funct Neurosurg* 82:14-19, 2004.

6. Fiegele T, Feuchtner G, Sohm F, Bauer R, Anton J, Gotwald T, Twerdy K, Eisner W: Accuracy of stereotactic electrode placement in deep brain stimulation by intraoperative computed tomography. *Parkinsonism and Related Disorders* 14:595-599, 2008.
7. Hamani C, Saint-Cyr J, Fraser J, Kaplitt M, Lozano A: The subthalamic nucleus in the context of movement disorders. *Brain* 127:4, 2004.
8. Hamid N, Mitchell R, Mocoft P, Westby G, Milner J, Pall H: Targeting the subthalamic nucleus for deep brain stimulation: technical approach and fusion of pre-and postoperative MR images to define accuracy of lead placement. *British Medical Journal* 76:409-414, 2005.
9. Iseki H, Kawamura H, Tanikawa T, Kawabatake H, Taira T, Takakura K, Dohi T, Hata N: An image-guided stereotactic system for neurosurgical operations. *Stereotact Funct Neurosurg* 63:130-138, 1994.
10. Kleiner-Fisman G, Herzog J, Fisman D, Tamma F, Lyons K, Pahwa R, Lang A, Deuschl G: Subthalamic nucleus deep brain stimulation: summary and meta-analysis of outcomes. *Movement Disorders* 21, 2006.
11. Lang A, Lozano A: Parkinson's disease first of two parts. *New England Journal of Medicine* 339:1044-1053, 1998.
12. Limousin P, Krack P, Pollak P, Benazzouz A, Ardouin C, Hoffmann D, Benabid A: Electrical stimulation of the subthalamic nucleus in advanced Parkinson's disease, 1998, pp 1105-1111.
13. Limousin P, Pollak P, Benazzouz A, Hoffmann D, Le Bas J, Broussolle E, Perret J, Benabid A: Effect of parkinsonian signs and symptoms of bilateral subthalamic nucleus stimulation. *Lancet* 345:91, 1995.
14. Maciunas R, Galloway Jr R, Latimer J: The application accuracy of stereotactic frames. *Neurosurgery* 35:682, 1994.
15. Menuel C, Garnero L, Bardinet E, Poupon F, Phalippou D, Dormont D: Characterization and correction of distortions in stereotactic magnetic resonance imaging for bilateral subthalamic stimulation in Parkinson disease. *J Neurosurg* 103:256-266, 2005.
16. Parent A, Hazrati L: Functional anatomy of the basal ganglia. I. The cortico-basal ganglia-thalamo-cortical loop. *Brain Research Reviews* 20:91-127, 1995.
17. Patel N, Heywood P, O'Sullivan K, Love S, Gill S: MRI-directed subthalamic nucleus surgery for Parkinson's disease. *Stereotact Funct Neurosurg* 78:132-145, 2002.
18. Pinsker M, Herzog J, Falk D, Volkmann J, Deuschl G, Mehdorn M: Accuracy and distortion of deep brain stimulation electrodes on postoperative MRI and CT. *Zentralblatt f?r Neurochirurgie* 69:144, 2008.
19. Pollak P, Krack P, Fraix V, Mendes A, Moro E, Chabardes S, Benabid A: Intraoperative micro-and macrostimulation of the subthalamic nucleus in Parkinson's disease. *Movement Disorders* 17, 2002.
20. Richter E, Hoque T, Halliday W, Lozano A, Saint-Cyr J: Determining the position and size of the subthalamic nucleus based on magnetic resonance imaging results in patients with advanced Parkinson disease. *Journal of neurosurgery* 100:541, 2004.
21. Schrader B, Hamel W, Weinert D, Mehdorn H: Documentation of electrode localization. *Movement Disorders* 17, 2002.
22. Shin M, Lefaucheur J, Penholate M, Brugi?res P, Gurruchaga J, Nguyen J: Subthalamic nucleus stimulation in Parkinson's disease: Postoperative CT?MRI fusion images confirm accuracy of electrode placement using intraoperative multi-unit recording. *Neurophysiologie Clinique/Clinical Neurophysiology* 37:457-466, 2007.
23. Sumanaweera T, Adler Jr J: Characterization of Spatial Distortion in Magnetic Resonance Imaging and Its Implications for Stereotactic Surgery. *Neurosurgery* 35:696, 1994.
24. Temel Y, Visser-Vandewalle V, Aendekerk B, Rutten B, Tan S, Scholtissen B, Schmitz

- C, Blokland A, Steinbusch H: Acute and separate modulation of motor and cognitive performance in parkinsonian rats by bilateral stimulation of the subthalamic nucleus. *Experimental Neurology* 193:43-52, 2005.
25. Volkmann J, Allert N, Voges J, Weiss P, Freund H, Sturm V: Safety and efficacy of pallidal or subthalamic nucleus stimulation in advanced PD, AAN Enterprises, 2001, pp 548-551.
 26. Wang X, Chang C, Geng N, Li N, Wang J, Ma J, Xue W, Zhao W, Wu H, Wang P: Long-term effects of bilateral deep brain stimulation of the subthalamic nucleus on depression in patients with Parkinson's disease. *Parkinsonism and Related Disorders*, 2009.

Acknowledgements

none

September 12, 2009

#47

Abstract Title:

What is the key point for the long- term successful DBS for Parkinson disease?

Primary Presenter:

Hidehiro Hirabayashi, M.D.,Ph.D.

Primary Presenter Institution:

Department of Neurosurgery, Nara Medical University, Kashihara, JAPAN

Co-presenter(s):

Kentaro Tamura M.D.

Co-presenter(s):

Hiroyuki Nakase M.D., Ph.D.

Presenting author's full street address and e-mail address:

hidehiro@narmed-u.ac.jp

Shijo-cho 840, Kashihara, NARA 634-8521, JAPAN

Introduction

The deep brain stimulation (DBS) therapy for advanced cases of Parkinson disease (PD) is established as a standard therapy, however, the long –term outcome is various in each patients. We investigated the key points for lasting the effects of the DBS for PD.

Materials and Methods

The subjects consisted of 34 patients who underwent STN- DBS and were followed over two years. They consisted of 13 males and 21 females with an average age of 63.7 years. Their period of illness was 11.6 years in average.

The MRI guided stereotactic surgery with micro-recording and semi-micro stimulation was performed in all patients under propofol anesthesia.

The DBS leads were implanted into both subthalamic nucleus and then the neuro-pace makers were implanted in the anterior chest after the 1 week preliminary stimulation.

We study the relationship between long-term outcome and the various factors including age, initial symptom, the period of illness, preoperative severity of the PD and stimulation parameters.

Results

There was no significant difference between the long-term outcome and the age or initial symptom. It seemed that the longer period of illness resulted in un-favorite outcome. There was a significant relationship between the preoperative severity of the illness and the outcome. Even if the clinical effect was getting worse, it was often corrected by adjustment of the parameters at O.P.D.

Conclusion

It is essential that the meticulous adjustment of parameters at the outpatient department for the long-term successful DBS therapy for the patients with advanced PD.

Learning Objectives:

1. deep brain stimulation
2. subthalmaic nucleus
3. long-term outcome

September 12, 2009

#49

Abstract Title:

A MEMS-based fully-integrated wireless neurostimulator

Primary Presenter:

Will Rosellini, MS Neuroscience

Primary Presenter Institution:

MicroTransponder Inc.

Dallas, Texas USA

Presenting author's full street address and e-mail address:

12147 Leuders Ln. Dallas TX 75230

will@microtransponder.com

Introduction

We report design, fabrication and *in-vivo* animal testing of a MEMS-based fully-integrated fully-biocompatible minimally-invasive wireless battery-free neurostimulator (3.1 x 1.5 x 0.3 mm) for chronic pain relief application. The device consists of spiral coil for inductive power coupling, rectification diodes, an ASIC neurostimulator circuit chip, biphasic platinum-iridium (PtIr) stimulation electrodes, interconnection between parts, and biocompatible SU-8 [1] packaging. The wireless neurostimulator was implanted subcutaneously in a rat and cortical responses evoked by wireless stimulation were repeatedly recorded.

Electrical stimulation has widely used to elicit or modify certain behaviors, to restore sensory perception, or to treat neurological disorders. Predominant methods of electrical stimulation involve delicate surgical procedure to implant relatively large electrodes with long electrical lead wires to connect with bulky electronic controllers. Such methods can cause the risk of infection and reduction of the functional reliability related to problems with wiring or physical motion of the implanted device. Inductively coupled wireless power transmission is a promising solution to address such issues. However, sizes of reported wireless inductive power devices [2, 3] are relatively large.

A schematic view of the wireless neurostimulator is shown in Figure 1. It consists of a round spiral inductor as a coupling element, diodes responsible for rectifying induced AC voltage, an ASIC chip to control stimulus current, and bipolar stimulating electrodes as neural interfaces. SU-8 was used as packaging material due to its biocompatibility. For the purpose of compact integration of those components, a SU-8 based socket platform was devised to tightly fit in rectifying diodes and the ASIC chip. A 1 mm diameter spiral inductor was embedded in the platform. The socket dimensions were decided by the dimensions of commercially available Schottky diodes (830 \times 300 \times 95 μ m) and the ASIC chip (1 \times 1 \times 0.15 mm). The contact pads at the bottom floor of each socket are to make interconnection between each component. Tiny amount of conductive epoxy was applied on each contact pad, and the ASIC and diodes were slid into the fabricated sockets. After integration process was completed, the whole device was completely sealed by another layer of SU-8. Finally, 1 mm diameter PtIr stimulating electrodes were attached on both sides of the device. Figure 2 illustrates fabrication sequence and Figure 3 shows the successfully fabricated SU-8 based wireless neurostimulator (3.1 \times 1.5 \times 0.3 mm).

Prior to the animal study, wireless stimuli were recorded during open-air tests for calibration across RF power levels at different separation distances between the wireless simulator and RF power coil as shown in Figure 4. The stimulus discharge time constant was consistently about 1 μ s, decaying from a peak stimulus voltage which depended upon the applied RF power level and separation distance up to a maximum of about 6.5 V at 1 Watt power and 1 mm separation down to stimulus failure at distances over 5 mm. After open-air tests, the fabricated device was placed subcutaneously upon the peroneal nerve of a rat and recorded the cortical responses to wireless stimulation powered by an external RF coil applied to the skin over the implant. Figure 5 illustrates the subcutaneous placement of a wireless stimulator and the external RF coil on the skin overlying the implant, which was prepared to mimic the configuration planned for human trials. As can be seen in Figure 6, increasing wireless stimulation intensity by increasing external RF power resulted in an increase in the amplitude of the evoked cortical responses. Fairly substantial cortical response was detected with wireless RF power as low as 21 dBm (125 mW) at 394 MHz.

Sung-Hoon Cho¹, Will Rosellini^{2,3}, and Jeong-Bong (JB) Lee

Acknowledgements

MicroTransponder Inc., University of Texas at Dallas, Texas Emerging Technology Fund

References:

[1] G. Voskerician et al., *Biomaterials*, 24 (2003), pp. 1959-1967

[1] M. Ghovanloo and K. Najafi, *IEEE Trans. Neural Syst. and Rehabil. Eng.*, 15 (2007), pp. 449-457

[2] L.S. Theogarajan, *IEEE J. Solid State Circuits*, 43 (2008), pp. 2322-2337

September 12, 2009

#50

Abstract Title:

Reversing Pathological Neural Plasticity to Treat Tinnitus

Primary Presenter:

Will Rosellini, MS Neuroscience

Primary Presenter Institution:

MicroTransponder Inc.

Dallas, Texas USA

Presenting author's full street address and e-mail address:

12147 Leuders Ln. Dallas TX 75230

will@microtransponder.com